



MAGNETIC RESONANCE IMAGING OF BRAIN NEUROBLASTOMA BASED ON NITROXIDE REDOX CYCLE

Zh. Zhelev^{1*}, R. Bakalova¹, S. Shibata¹, V. Gadjeva², L. Spasov³, I. Aoki¹

¹Molecular Imaging Center, National Institute of Radiological Sciences (NIRS), 4-9-1 Anagawa, Inage-ku, Chiba, Japan;

²Medical Faculty, Trakia University, Stara Zagora, Bulgaria;

³Medical Faculty, Sofia University, Sofia, Bulgaria

ABSTRACT

In the present study we propose a new diagnostic methodology for non-invasive imaging of tissue red/ox activity in intact healthy and cancer-bearing mammals, which allows a differentiation of cancer development from normal (healthy) condition. The method is based on red/ox cycle of cell-permeable nitroxide radicals and their MRI contrast properties, which makes them useful molecular sensors for tissue red/ox activity. The nitroxide radical (which is characterized by T₁ contrast) participates in electron-transfer reactions with the intracellular reactive oxygen species and reducing equivalents with formation of non-contrast intermediate products, which is accompanied with MRI signal decay. The half-life of MRI signal decay ($t_{1/2}$) was used as a marker of tissue red/ox activity to the nitroxide probe.

The experiments were conducted on healthy and cancer-bearing mice. The mice were under anesthesia during the MRI measurements. All measurements were conducted on 7 Tesla MRI.

In healthy mice, the half-life of MRI signal decay in the selected regions of interest (ROI; brain and surrounding tissues) was considered as a reference steady-state value, which is indicative of tissue red/ox activity in norm. In cancer-bearing mice, the half-life of MRI signal decay in the same or similar ROI was markedly different from this reference value. The results demonstrated that the normal (healthy) tissues possessed a significantly higher reduction activity to the nitroxide probe in comparison with cancer tissue, which could be an appropriate diagnostic marker for carcinogenesis.

Key words: Nitroxide Radicals, Magnetic Resonance Imaging, Cancer, Tissue Redox Activity

INTRODUCTION

It is widely accepted that the balance between the reactive oxygen species (ROS) and reducing equivalents (RE) in cells, tissues and physiological fluids determines their red/ox status, as well as their red/ox activity to exogenous compounds. Over 50-years experience in free radical biology and medicine shows that the levels of ROS and RE are very different in the tissues of healthy and cancer-bearing mammals and the abnormal generation of ROS provokes genomic instability and cancer development, which

could be a key to the successful cancer therapy (1-4).

In the present study, we proceeded from the assumption that the red/ox activities of normal (healthy) and cancer tissues, based on their ROS/RE balance, are also different and this parameter could be used as a diagnostic marker for carcinogenesis and a prognostic marker for the efficiency of cancer therapy. The study was directed to the development of new diagnostic approach for imaging of cancer using cell-permeable and red/ox sensitive nitroxide probes. The method is based on red/ox cycle of nitroxide radical (**Figure 1**). The nitroxide radical (which is characterized with T₁ contrast) participates in electron-transfer reactions with ROS and RE with formation of non-contrast intermediate products (hydroxylamine and oxoammonium ion) (5-9).

*Correspondence to: Zhivko Zhelev, Molecular Imaging Center, National Institute of Radiological Sciences (NIRS), 4-9-1 Anagawa, Inage-ku, Chiba 263-8555, Japan. E-mail: zh_zhelev@yahoo.com

The reduction of nitroxide radical to hydroxylamine and the oxidation of hydroxylamine to the radical form are assumed to be dominant processes at physiological pH 7.4 (8). The rate constants of these reactions determine the MRI signal decay of nitroxide radical in living cells and tissues (5-7, 9).

In healthy animals, the half-life of MRI signal decay ($t_{1/2}$) in the selected region of interest (ROI; for example, brain tissue) could be considered as a reference steady-state level of tissue red/ox activity in norm. We supposed that in cancer-bearing animals, the half-life of MRI signal decay in the same ROI has to be different from this reference level.

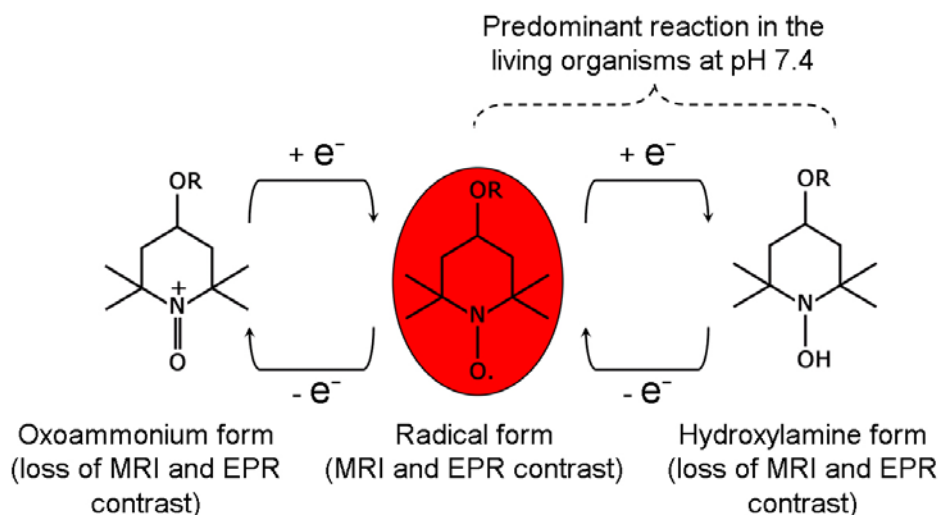


Figure 1. Red/ox cycle of nitroxide radical.

MATERIALS AND METHODS

All experiments were conducted in accordance with the guidelines of the Physiological Society of Japan and were approved by the Animal Care and Use Committee of the National Institute of Radiological Sciences, Chiba, Japan.

The nitroxide probe (nitroxide-labeled nitrosourea, SLENU) was synthesized and purified in the Department of Chemistry and Biochemistry of the Medical Faculty, Trakia University, Bulgaria.

The animals (Balb6 nude mice) were separated in two groups: healthy mice (controls; $n=6$) and mice with brain neuroblastoma (cancer-bearing mice; $n=7$). In both groups, the mice were same age, almost same weight (~25 g), and kept under same conditions. Neuro2a cells (0.5×10^5 cells in 10 μ L) were inoculated in one hemisphere of the brain and the MRI measurements were performed on the 7th-8th day after inoculation (**Figure 2**). The cancer cells initiate a development of brain neuroblastoma without significant angiogenesis within ~10 days after inoculation.

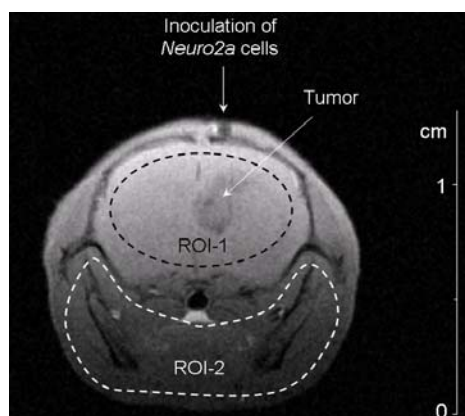


Figure 2. MR image (spin-echo sequence) of tumor in mouse brain obtained 8 days after inoculation of Neuro2a cells in Balb6 nude mouse. The dotted lines indicate the regions of interests (ROI-1 – brain tissue; ROI-2 – surrounding tissues).

The MRI measurements were conducted on 7.0 Tesla horizontal magnet (Kobelco and Jastec, Japan) interfaced to a Bruker Avance console (Bruker BioSpin, Germany) and controlled with ParaVision 4.0.1 (Bruker BioSpin, Germany).

The mice were anesthetized by isoflurane (1.2%) and placed in a head holder (Rapid Biomedical, Germany) with fixed had. A respiration sensor (SA Instruments, NY, USA) was placed on the back of the mouse. A non-magnetic temperature probe (FOT-M and FTI-10, FISO Technology, Germany) was used to monitor the rectal temperature. The tail vein was cannulated by polyethylene tube (PE-10, Becton-Dickinson, NJ, USA) for drug administration. The mouse was then placed in the ¹H-volume radio-frequency (RF) resonator (Bruker BioSpin) with surface RF receiver (Rapid Biomedical, Germany), which was pre-warmed using a body temperature controller (Rapid Biomedical). The resonator units, including the mouse, were placed in the magnet bore. The mouse body temperature was kept at 37 +/- 1 °C during the MR measurements. Before the measurements after drug injection, five control images of the mouse brain were taken with the following parameters: T₁-weighted incoherent gradient-echo sequence (fast low-angle shot; FLASH), repetition time (TR) = 75 ms; echo time (TE) = 3.5 ms; flip angle (FA) = 45 degrees; field of view (FOV) = 3.2 x 3.2 cm; number of averages = 4; scan time = 19.6 seconds; matrix = 64 x 64; slice thickness = 1.0 mm; number of slices = 4. We selected coronal slice orientations with a 500 um x 500 um x 1000 um nominal voxel resolution.

The MRI scanning was started and one minute and forty seconds after that SLENU (100 mM stock-solution in DMSO) was injected via the tail vein (100 μL per 25 g mouse) without scan-breaking. T₁-weighted images were acquired continuously within ~14 min. Mice, injected with DMSO only (in the same volume), served as negative controls.

The MRI data were analyzed using the *ImageJ* software (National Institute of Health, MD, USA).

RESULTS

Two ROI were selected in the MR images – brain tissue (cortex) and soft tissues surrounding the brain (**Figure 2** – dotted lines). The first 5 frames of MRI data (before injection of SLENU) were used for calculation of the averaged baseline level. All data were normalized to the baseline.

Figure 3 shows the kinetic curves of the normalized MRI signal in the brain after injection of SLENU in control mice (A) and cancer-bearing mice (B). There was a large difference between the profiles of both histograms. In healthy mice, the MRI signal intensity in ROI increased slightly after injection of SLENU, followed by rapid decay (**Figure 3A**). The half-life of MRI signal decay was about 1 min or 2 min 20 sec in the brain or surrounding tissues, respectively. These $\tau_{1/2}$ values are indicative of a high reduction activity of the normal (healthy) brain and surrounding tissues to the injected nitroxide probe. They were considered as reference values for the red/ox activity of the respective tissues in norm. In cancer-bearing mice, the MRI signal intensity increased after the injection of SLENU and remained high and stable over 14 min, without decay (**Figure 3B**). The half-life of MRI signal decay can be considered for more that 14 min. This is indicative of a low reduction activity of the brain and surrounding tissues of cancer-bearing mice to the injected nitroxide probe. It was also observed that SLENU was accumulated in the cancer tissue and the MRI signal increased markedly and remained stable in the cancer hemisphere within 14 min scan-time (**Figure 4**).

CONCLUSIONS

The present study demonstrates a development of new diagnostic approach for carcinogenesis based on the different tissue red/ox activity of normal and cancer-bearing mammals and its imaging by cell permeable nitroxide SLENU and MRI. There is a very clear difference between MRI signal dynamics in normal (healthy) brain and cancer-bearing brain after injection of SLENU, which is indicative of the different metabolic (red/ox) activity of both tissues. The half-life of MRI signal decay is an appropriate diagnostic marker for carcinogenesis. The described methodology is also applicable in isolated tissue specimens (e.g., biopsy specimens).

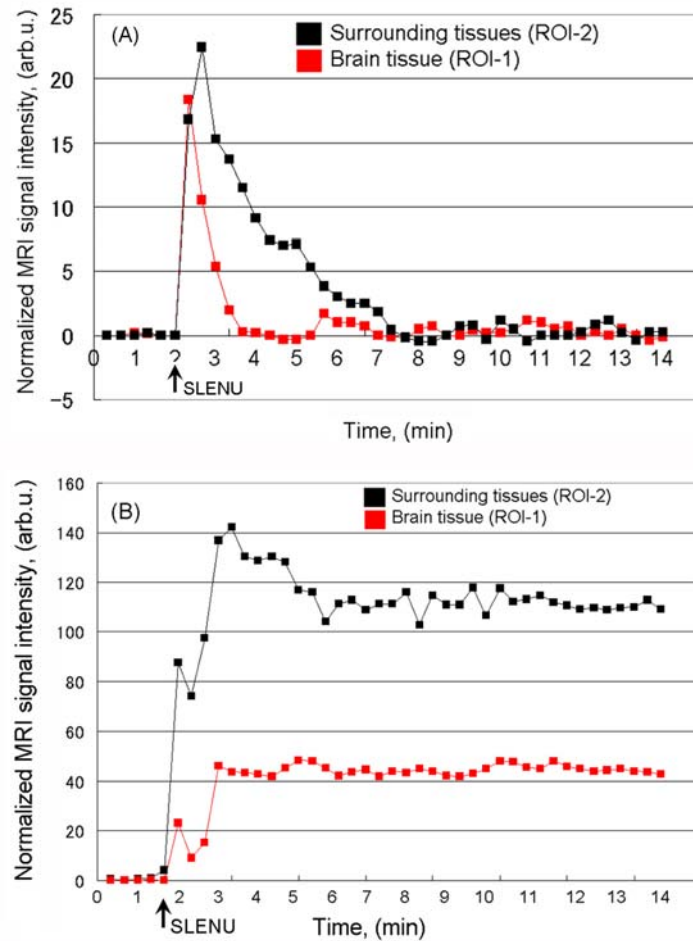


Figure 3. MRI signal dynamics of SLENU in the brain (ROI-1) and surrounding tissues (ROI-2) of healthy (A) or cancer-bearing mice (B) under continuous scanning within 14 min. The data are mean from 6 or 7 animals.

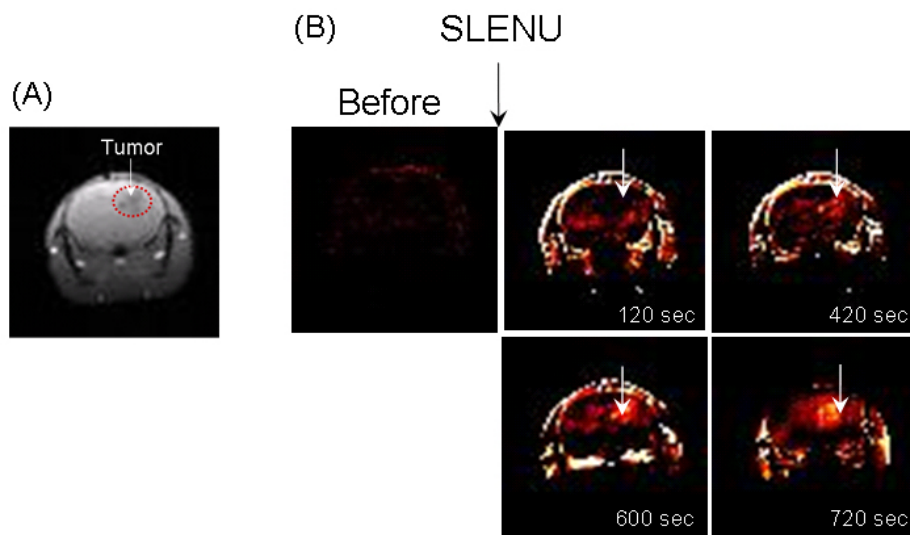


Figure 4. (A) MRI image (gradient-echo sequence) of brain neuroblastoma in mouse. (B) Extracted MRI signal intensity in the same cancer-bearing mouse, obtained on the 2nd, 7th, 10th and 12th min after injection of SLENU.

REFERENCES

1. Fang, J., Seki, T. and Maeda, H., Therapeutic strategies by modulating oxygen stress in cancer and inflammation. *Adv Drug Deliv Rev*, 61:290-302, 2009.
2. Miller, T.W., Isenberg, J.S. and Roberts, D.D., Molecular regulation of tumor angiogenesis and perfusion via redox signaling. *Chem Rev*, 109:3099-3124, 2009.
3. Pani, G., Giannoni, E., Galeotti, T. and Chiarugi, P., Redox-based escape mechanism from death: the cancer lesson. *Antioxid Redox Signal*, 11:2791-2806, 2009.
4. Landriscina, M., Maddalena, F., Laudiero, G. and Esposito, F., Adaptation to oxidative stress, chemoresistance, and cell survival. *Antioxid Redox Signal*, 11:2701-2716, 2009.
5. Rosen, G.M., Cohen, M.S., Britigan, B.E. and Pou, S., Application of spin traps to biological systems. *Free Radic Res Commun*, 9:187-195, 1990.
6. Soule, B.P., Hyodo, F., Matsumoto, K., Simone, N.L., Cook, J.A., Krishna, M.C. and Mitchell, J.B., Therapeutic and clinical applications of nitroxide compounds. *Antioxid Redox Signal*, 9:1731-1743, 2007.
7. Hyodo, F., Soule, B.P., Matsumoto, K., Matsumoto, S., Cook, J.A., Hyodo, E., Sowers, A.L., Krishna, M.C. and Mitchell, J.B., Assessment of tissue redox status using metabolic responsive contrast agents and magnetic resonance imaging. *J Pharm Pharmacol*, 60:1049-1060, 2008.
8. Trnka, J., Blaikie, F.H., Smith, R.A. and Murphy, M.P., A mitochondria-targeted nitroxide is reduced to its hydroxylamine by ubiquinol in mitochondria. *Free Radic Biol Med*, 44:1406-1419, 2008.
9. Zhelev, Z., Bakalova, R., Aoki, I., Matsumoto, K., Gadjeva, V., Anzai, K. and Kanno, I., Nitroxyl radicals for labeling of conventional therapeutics and noninvasive magnetic resonance imaging of their permeability for blood-brain barrier: relationship between structure, blood clearance, and MRI signal dynamic in the brain. *Mol Pharm*, 6:504-512, 2009.