



PROSTATE GLANDS AND MUSCLE TISSUE OF BOYS IN THE FETAL PERIOD

A. Usovich*, I. Piatsko

Educational Establishment «Vitebsk State Order of Peoples' Friendship, Medical University», Vitebsk, Republic of Belarus

ABSTRACT

The purpose of the study was to determinate the morphometric parameters of epithelial cords, prostatic ducts, acini of the human prostate gland and their lining epithelium, the shape of prostate glands and muscle tissue in fetal periods of development. The study was performed on 19 prostate glands of boys of intermediate and late fetal periods.

The formation of prostatic ducts was not followed by increase in their total area and was the result of differentiation epithelial cells and apoptosis. Transformation of prostate glands in the prenatal period occurs in a certain sequence: the formation of epithelial buds, their canalization by apoptosis with formation of epithelial ducts and prostatic ducts and formation of end pieces of prostate glands from these ducts. In prenatal periods, the structure and orientation of smooth muscle bundles around the glands can not provide evacuation of the contents of the prostate glands.

Key words: apoptosis; canalization; prostate development

INTRODUCTION

Pathology of the prostate takes a leading place in the structure of diseases in modern men. The results of studies of cell biology, histology, pathological anatomy, clinical observations have explained some causes of prostate disease, including the most common of these BPH (1-4). However, the multifactorial nature and the lack of established certainty about the etiology and pathogenesis of BPH still necessitates finding answers to these questions. There are suggestions that changes in the prostate in older men are manifestations of developmental disorders of the glands and muscles of the organ in embryonic and fetal periods (5), and the development of pathological changes in the prostate may be a consequence of the process of impaired organ development (6). A closer study of the processes of morphogenesis in the pathologically unchanged prostate can facilitate the understanding of the occurrence

of atypical forms of glands and muscle bundles. There are descriptions of metaplasia of the epithelium in the lumen of the forming prostate glands and prostatic ducts (7), and as the prostate glands mature, such foci become less visible and less common. Bruni-Cardoso A. has suggested the formation of lumens in the end pieces of the prostate glands in the rats' fetuses through apoptosis (8). In connection with the above-stated, we have conducted the study of transformations of the glands and muscles of the prostate from the fetal period to old age, a fragment of which is presented in the article.

Objective: to investigate the formation and transformation of glands and muscle tissue in the human prostate of the fetus.

MATERIALS AND METHODS

The study was performed on 19 prostates of human fetuses from 14 to 40 weeks of intrauterine growth which had died from causes not related to violations of urogenital apparatus (based on conclusions of the protocols of pathoanatomical researches). The study was performed in accordance with the provisions of the Declaration of Helsinki and

*Correspondence to: Usovich A.K., Educational establishment «Vitebsk State Order of Peoples' Friendship Medical University» Republic of Belarus, 210009, Vitebsk, Frunze Ave, 27, e-mail: usovicha@mail.ru

with the law of the Republic of Belarus no. 55-3 "On Burial and Funeral Business", as amended by act no. 2-2235.

The study protocol was approved by the independent ethics committee of Vitebsk State Medical University (№2 / 07.05.2018). Fetus prostates were fixed in 10% formalin solution. The fixed prostate was cut in the sagittal, frontal and horizontal planes, embedded in paraffin according to the standard technique. Sections of 5 μ m thick were prepared with a Leica RM 2125 RT rotary microtome (Germany). Histological sections were stained with hematoxylin–eosin, fuxelin according to Hart. The material was divided into 2 age groups according to embryologic terminology – intermediate fetal and late fetal periods. All fetus prostates were examined and photographed under magnification using the microscope DM 2000 manufactured by Leica and the «Leica D-LUX 3» digital camera (Germany). The micrographs of the prostate glands were processed with the use of the Image Fiji software (9,10) using the set of standard tools and plugins. We used the morphometric method of verification of apoptotic cells on stained histological preps using the criteria of apoptosis as recommended by Skibo (11). Morphometric research included measurements of acini and acinar lumen areas, epithelium height, assessment of shape factors (roundness, Feret diametr) (10). Statistical hypotheses were tested using Microsoft Excel 2007 software and Statistica 10.0. The statistical heterogeneity of the samples was tested using nonparametric ANOVA procedures (Kruskal_Wallis test for multiple comparisons). When a statistical heterogeneity of several samples was found, subsequent identification of heterogeneous

groups was performed using the Mann – Whitney U test and Dunn's post hoc test with the Bonferroni correction. Differences were considered to be significant when $p < 0.05$.

RESULTS

In the prostate of fetus of the intermediate fetal period (14–26 weeks) glandular constructions of different levels of maturity were observed. Round epithelial cords were filled with epithelial cells and bounded by basal membrane. Epithelial tubules had a lumen of different sizes and shapes, and showed no polarization with respect to the basal lamina. In prostatic ducts and acini of the first and second order, the polarization of the epithelial cells was detected with respect to the basal lamina (**Figure 1**).

During this age period, the number of epithelial cords and epithelial tubules dominated over the number of prostatic ducts and the formed glands.

The area of epithelial cords was 1.1 times less ($p < 0.05$) of the areas of acini (**Table 1**). In the late fetal period, in comparison with the intermediate fetal period, the statistically significant change in the size of epithelial cords and prostatic ducts ($p > 0.05$) was not detected. Along with quantitative transformations in the late fetal period, changes in the shape of the glands and their lumen occurred. A sequence of transformation of epithelial cords into the acini in the prenatal period occurs in a specific order, regardless of the age and location of these structures in the developing prostate.

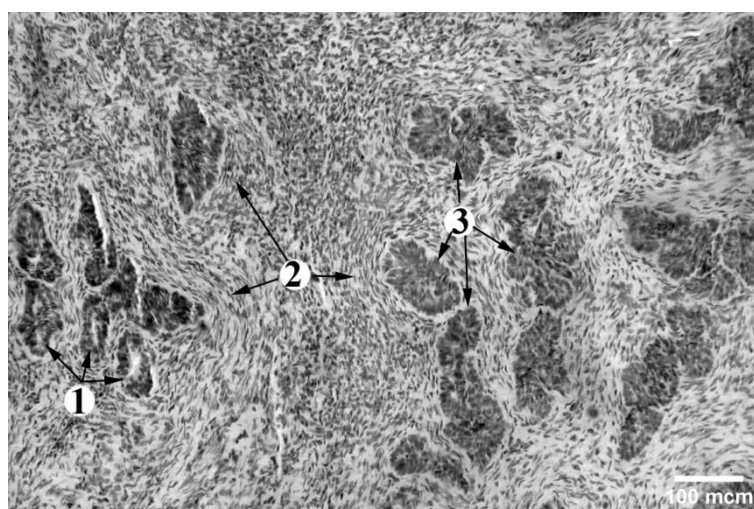


Figure 1. Fetal prostate preparation (week 22). Staining with hematoxylin and eosin.

1. Prostatic ducts. Epithelial cells of the prostatic duct with basally located nuclei
2. Smooth muscle bundles
3. Epithelial cord with epithelial cells tightly adjoining each other. Epithelial cells contain large nuclei without signs of polarization.

Table 1. Prostate gland size and factors of shape in intermediate and lateral fetal periods
Results are represented as *M* (1st *Qu*; 3rd *Qu*), where *M* is median and first *Qu* and third *Qu* are the first and third quartiles, respectively

| | Epithelium height, μm | Epithelium cord area, μm^2 | Acinar area, μm^2 | Acinar lumen area, μm^2 | Roundness of acini | Roundness of lumens | Feret diametr of acini | Feret diametr of acinar lumens |
|---------------------------|----------------------------------|---------------------------------------|------------------------------|------------------------------------|---------------------|----------------------|------------------------|--------------------------------|
| Intermediate fetal period | 12,74 (10,1;15,7) | 4244 (2981;6758) | 4769 (3247;7535) | 149 (95;289) | 0,74 (0,66;0,8) | 0,70 (0,57; 0,78) | 105 (86;124) | 20 (14;34) |
| Late fetal period | 15,5* (12,2;18,97) | 4516 (3100;7244) | 5967* (4092;9562) | 565* (301;987) | 0,79 (0,65;0,82) | 0,64 (0,49;0,76) | 112 (84;148) | 72* (42;11) |

Stage 1. The formation of epithelial tubules. The canalization of epithelial cords is made by apoptosis. It is manifested in formation of slit-like gaps within the epithelial cords due to reduction of sizes of individual epithelial cells and loss of intercellular contacts. Transforming epithelial cells had changes in contour: roundness of a cell contour, indentation and protrusion on the cell surface. Nuclei of changed epithelial cells had an uneven contour, a bladed look, in some cases they broke up into micronuclei. Epithelial cords and prostatic tubules were surrounded by single myocytes.

Stage 2. Formation of prostatic ducts. Prostatic ducts are formed as a result of canalization of epithelial cords and epithelial tubules. At the same time, their epithelium is

Stage 3. Formation and growth of acini.

reorganized into two different cell populations: basal epithelial cells localized along the basement membrane, represented by cubic epithelial cells, and the inner cell layer formed by flat or cubic cells. We have found apoptotic bodies throughout the entire prenatal period within the emerging prostatic ducts. From 11-12 weeks of fetal development we have observed the first signs of canalizations of the prostatic ducts. The canalization of the prostatic ducts occurs in direction from the urethra to the acini. Around the prostatic ducts were detected bundles of myocytes located mainly circularly and longitudinally but without a visually determined connection with the prostatic ducts (**Figure 2**).

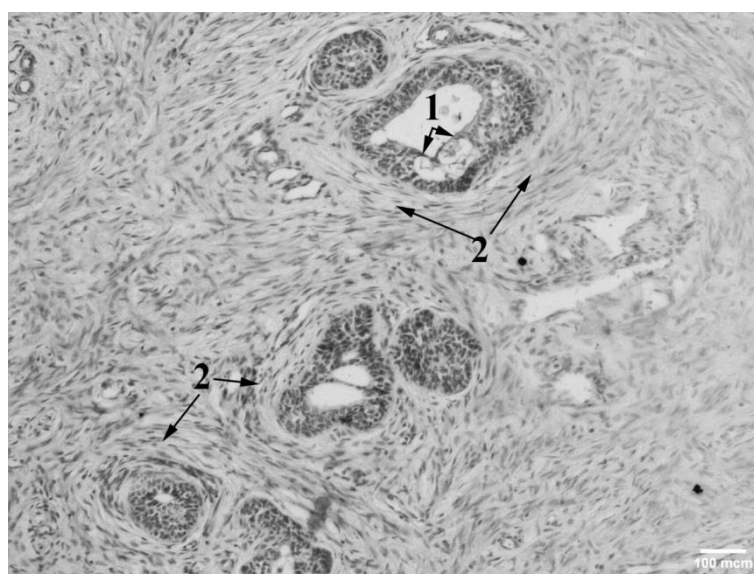


Figure 2. Fetal prostate preparation (week 38). Staining with hematoxylin and eosin. 1—conglomerates of apoptotic cells in the prostatic ductal lumens. 2. Smooth muscle bundles

In the early prenatal period, we have identified the formation of acini of the first order at the distal ends of the prostatic ducts. In intermediate and late fetal periods the acini of the second and third order were found. In the intermediate fetal period the part of the glands has a typical prostate-alveolar-tubular structure. In the late fetal period compared to the intermediate fetal period the acini area was increased in 1.1 times ($p < 0.05$). An insignificant increase of the specific area of the glandular parenchyma in the organ of transformation of the developing glands occurs mainly due to their canalization (the area of acinar lumens increases by 3.8 times ($p < 0.05$)). In the fetal period, changes in the shape of acinar lumens were detected ($p < 0.05$).

In the acini in the late fetal period, compared with the intermediate fetal period, the secretory epithelium was transformed from flat to cubic and the height of epithelial cells was increased in 1.2 times ($p < 0.05$). The epithelium lining the acini at this age did not differ from the epithelium of the prostatic ducts. The forming acini are loosely surrounded by multidirectional bundles of smooth myocytes. In areas of glands with formed prostate ducts and forming acini the number of apoptotic bodies prevailed in the sections of the prostatic ducts closest to the urethra, compared with their sections near the acini.

DISCUSSION

Our observations are consistent with the results of studies of rat prostate, which also showed that the formation of prostatic epithelial tubules and prostatic ducts is not followed by increase in the area and is the result of differentiation of epithelial cells (8). We do not agree with the previous assumptions that canalization of epithelial cords is the result of segregation of basal and secretory epithelial cells (12). The signs of canalization of epithelial cords into the prostatic ducts were found in different areas of prostate fetuses, which agrees with Bruni-Cardoso results (8).

This gave us the reason to assume that apoptotic bodies were removed from the lumen of the prostatic ducts by extrusion. This is inconsistent with the assumption of Marcer (13) that canalization should occur in the proximal-distal direction. Conglomerates of

apoptotic cells were observed closer to the urethra. This allowed us to assume that they were removed from ductal system by extrusion. The transformation of the prostate glands occurs in a specific sequence: epithelial cords, epithelial tubules, prostatic ducts and end pieces of the prostate glands.

In the prenatal period, the design and orientation of the smooth muscle bundles around prostatic ducts and acini do not ensure the evacuation of content of the prostate glands.

REFERENCES

1. Babinski, M., Chagas, M., Costa, W., Sampaio, F., Prostatic epithelial and luminal area in the transition zone acini: morphometric analysis in normal and hyperplastic human prostate. *BJU Int.*, 92:592-596, 2003.
2. Brössner, C., Petritsch, K., Fink K, Auprich, M., Madersbacher, S., Adlercreutz, H., Rehak, P., Petritsch, P., Phytoestrogen tissue levels in benign prostatic hyperplasia and prostate cancer and their association with prostatic diseases. *Urol.*, 64(4):707-711, 2004.
3. Chagas, M., Babinski, M., Costa, W., Sampaio, F., Stromal and acinar components of the transition zone in normal and hyperplastic human prostate. *BJU Int.*, 89(7):699-702, 2002.
4. Toftgard, R., Two sides to cilia in cancer. *Nat. Med.*, 15:994-996, 2009.
5. Timms, B., Hofkamp, L., Prostate development and growth in benign prostatic hyperplasia. *Differentiation*, 82(4-5):173-183, 2011.
6. Shapiro, E., Embriologic development of the prostate. Insights into the etiology and treatment of benign prostatic hyperplasia. *Urol.Clin North Am.*, 17(3):487-493, 1990.
7. Ernst, L., Ruchelli, E., Huff, D., Color Atlas of Fetal and Neonatal Histology, New York, Springer, 2011.
8. Bruni-Cardoso, A., Carvalho, H., Dynamics of the epithelium during canalization of the rat ventral prostate. *Anat. Rec.*, 290:1223-1232, 2007.
9. Schneider, C., Rasband, W., Eliceiri, K., NIH Image to ImageJ: 25 years of image analysis. *Nature Methods*, 9:671-675, 2012.
10. Mytsik, A., Using the ImageJ program for automatic morphometry in histological

- studies. Omsk Scientific Herald, 2(100):187-189, 2011.
11. Skibo, Y., Abramova, Z., Methods for the study of programmed cell death. Educational and methodological manual for masters at the rate of "Theory of apoptosis" Kazan, FGAOU VPO KFU, 2011.
 12. Hayward, S., Baskin, L., Haughney, P., Epithelial development in the rat ventral prostate, anterior prostate and seminal vesicle. *Acta Anat.*, 155:81-93, 1996.
 13. Marcer, P., Donjacour, A., Dahiya R., Hormonal, cellular and molecular control of prostatic development. *Dev. Biol.*, 253:165-174, 2003.