



MUSCULAR ABNORMALITIES IN SUBMENTAL TRIANGLE – VARIATIONS OF ANTERIOR BELLY OF DIGASTRIC MUSCLE

S. Novakov*, S. Delchev

Department of Anatomy, Histology and Embryology, Medical University – Plovdiv,
Plovdiv, Bulgaria

ABSTRACT

The aim of this study is to highlight some unusual morphology of the digastric muscle anterior belly. During dissection of the bodies used in the practical lessons for second year medical students we found abnormal pattern of the suprahyoid region in the necks of two adult male cadavers. Both were with variable anterior bellies of digastric muscles. **Case 1** presented a unilateral left variation, with an anomalous anterior belly. **Case 2** presented bilateral variation, with the presence of two supernumerary bellies. Though multiplicity of anterior belly is common we provide interesting variations with anatomical and clinical importance. The different variants of the anterior belly of the digastric muscle can be found during the routine dissection or surgical procedure or imaging techniques. Anatomical variations of the anterior bellies of the digastric muscles can be easily confused with pathological conditions in CT and MR imaging. It is necessary to recognize that variants of the digastric muscle may happen in order to escape confusion when diagnosing abnormal lesions of the floor of the mouth and submental region.

Key words: neck muscles, accessory belly, trigastric, mylohyoid, dissection

INTRODUCTION

The formation of the digastric muscle starts in the fourth week of the development with the origin of the myoblasts in the fourth somatomeres, followed by their migration into the first pharyngeal or Meckel arch. This stage is for the development of the anterior belly of digastric and the mylohyoid muscle with the mylohyoid nerve between them. Posterior belly is formed by the myoblasts of the sixth somatomeres reaching the second pharyngeal or Reichert arch (1). The nerve supply of the two bellies supports their different sources of origin from the mesenchyme of the first and second branchial arches.

Digastric is a two-bellied muscle which bridges between the mastoid process and mandible. The longer posterior belly is attached in the mastoid notch of the temporal bone, and points downwards and forwards. The anterior belly originates from the digastric

fossa, and goes downwards and backwards. Both bellies meet in an intermediate tendon that perforates stylohyoid and runs in a fibrous sling attached to the body and greater horn of the hyoid bone (2). The anterior belly of digastric is intimately related to the mylohyoid and the exchange of fibers, sometimes with complete fusion between them, is not unusual (3). Since both the digastric muscle and mylohyoid muscle develop from the first pharyngeal arch, their anomalies are often found simultaneously (4).

Computed tomography (CT) and magnetic resonance imaging (MRI) are more commonly used in diagnosis and staging tumors or other undifferentiated masses in the neck, and the dependence on the radiological modalities in managing patients has been only increasing. Therefore, it is important for physicians to be familiar with any variations of the neck muscles to avoid misinterpretations of the radiological images and make right treatment plans for their patients (4).

*Correspondence to: Stoyan Novakov, Dept. of Anatomy, histology and embryology, 15A "V. Aprilov" AV, Plovdiv 4002, Bulgaria, +359 83595981, email: stoyan67@gmail.com

CASE REPORT

Case 1 – An adult male cadaver dissected as a part of the teaching curriculum in the

department of anatomy in Plovdiv showed an extraordinary features of the suprahyoid region (**Figure 1**).

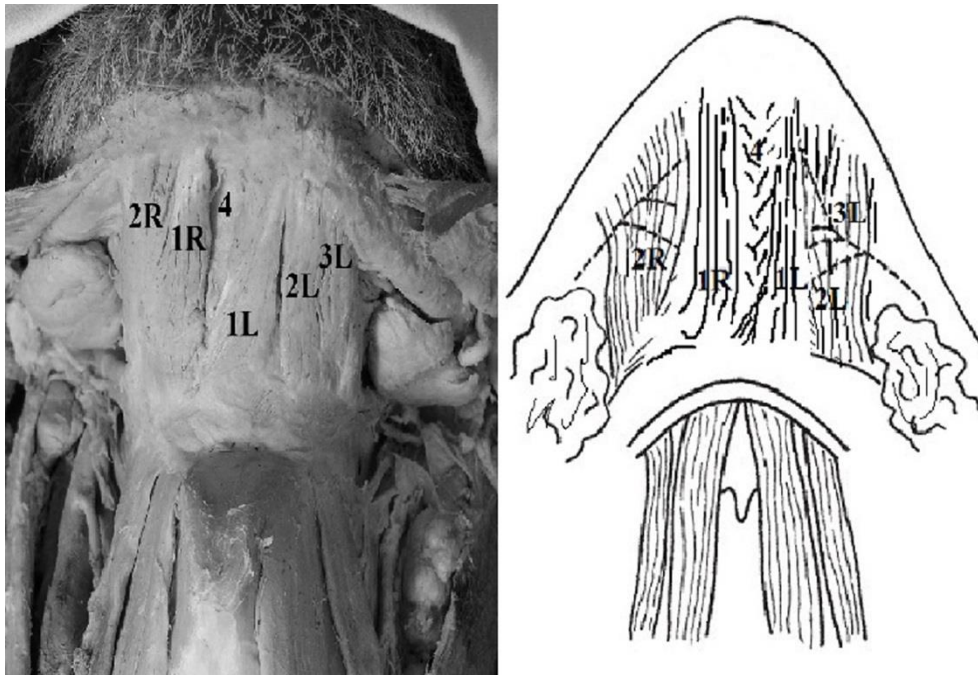


Figure 1. Suprahyoid region picture and drawing. 1R – right medial anterior belly; 2R – right lateral anterior belly; 1L – left medial anterior belly; 2L – left intermediate anterior belly; 3L – left lateral anterior belly; 4 – mylohyoid

Almost the entire submental triangle was covered with the anterior bellies of the digastric muscle. The anatomical variations of that muscle were bilateral and classified in the category of consistency. The right digastric had a posterior belly of 74 mm in length. The anterior bellies on the right side were two and the medial or the normal one ended on the digastric fossa. Its length was 38 mm and width at the mandible was 5 mm. The lateral or the variable one was 42 mm long and 13 mm wide at its attachment to the mandible. The left digastric was also variable. There were 3 anterior bellies on that side – medial (normal), intermediate and lateral which were supernumerary variations. The dimensions of the above mentioned were as follows: size on the hyoid medial – 13 mm, intermediate – 11 mm and lateral – 9 mm; on the mandible – 7 mm, 6 mm and 5 mm respectively. The slings of the intermediate tendon were 11 mm long on the right and 15 mm long on the left. The space between the two medial anterior bellies lined by the mylohyoid was a small triangle 22 mm long and 7 mm wide. The right posterior belly was 68 mm long.

Case 2 – The second cadaver dissected during the same semester as case 1 was an adult male with variation of the digastric muscle (**Figure 2**).

The examination of the dissected suprahyoid region showed trigasric formation on the left. An accessory anterior belly arose from the intermediate tendon of the left digastric. The extra belly of the muscle was with unusual course. It drew a triangle starting from the intermediate tendon to the mylohyoid raphe and next to the digastric fossa. The described fibers could be named as posterior and anterior part of the variable anterior belly of the digastric. The dimensions of the muscle bellies were as follows: posterior belly of the left digastric was 94 mm in length; the lateral anterior belly was 48 mm long; the posterior part of the medial or third belly of digastric was 34 mm long and the anterior part was 40 mm long. The posterior part of the variable belly was found deeper or superior to the normal one, while the fibers of the anterior part started from the end of the posterior at the raphe and ended on the digastric fossa together with the normal anterior belly. The right digastric was normal with posterior belly of 94

mm and anterior of 63 mm. There was an observable difference between the slings of the intermediate tendons on both sides. The one on the left was measured 19 mm long compared to

9 mm on the right side. We found no abnormalities of the mylohyoid and stylohyoid muscles in both cases.

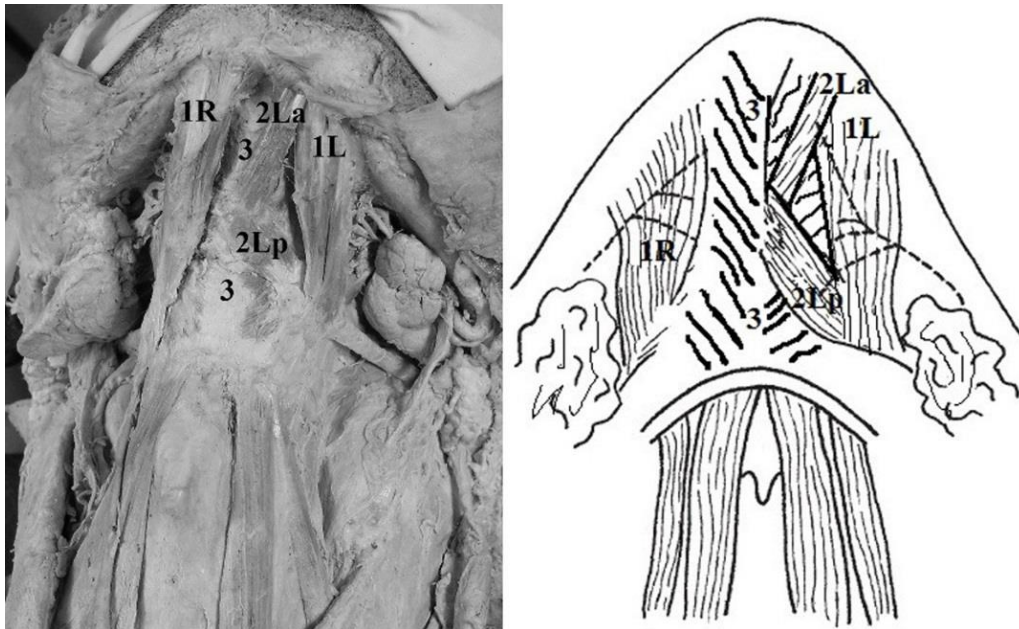


Figure 2. Suprahyoid region picture and drawing. 1R- right anterior belly of digastric; 1L - left anterior belly of digastric; 2Lp –posterior part of accessory anterior belly; 2La – anterior part of accessory anterior belly; 3 - mylohyoid

DISCUSSION

The origin of the anterior belly of digastric explains the big number and patterns of variations of this muscle. Kawai et al. are trying to explain this morphological diversity by the theory presented by Fürbringer at the end of 19th century and supported by Nishi (1938) in Japan, called the theory of nerve-muscle specificity. Anterior belly, receiving twigs of the mylohyoid and facial nerves, forms secondarily combining the most ventral and rostral part of the primordium of the stylohyoid muscle in the second branchial arch with the caudal part of the primordium of the anterior belly in the first branchial arch. Therefore, the anterior belly of the digastric muscle is located on the boundary between the first and second branchial arches. So it is the highly complex morphogenesis of the derivatives of the first branchial arch that could explain the variations of the muscle (5, 6). Natsis et al. explain that developmentally, the suprahyoid accessory muscle bundles are formed due to the abnormal splitting of the rudimentary embryonic muscle, the so-named muscle anlage. The duplication or multiplication could be attributed to

differentiation deficiency of the 1st pharyngeal arch mesoderm or the abnormal neural crest cells migration. The pharyngeal arches proximity allows for the development of accessory muscle fibers, which fuse with and cross the midline (7).

The variations of the anterior bellies of the digastric muscle can be found during the routine dissection or surgical procedure or imaging techniques.

Supernumerary variations of the anterior belly are a rather common. An accessory anterior belly, which may or may not cross the midline, has been reported in 66.7% of individuals; it has often been observed bilaterally or even symmetrically. An accessory anterior belly can arise from the intermediate tendon, the main anterior belly, the hyoid, the mandible or the digastric fossa (3, 7). Probable insertion points include the mylohyoid raphe, the hyoid bone, the mandible, the contralateral anterior belly of digastric, or even the mylohyoid muscle. Occasionally, accessory muscle bundles may fuse in the midline with the mylohyoid or cross the midline, superficial to it (7). In our 2 cases

there are accessory bellies of anterior digastric as bilateral in the first and unilateral in the second one. The unilateral accessory digastric originates from the intermediate tendon and belongs to type 2 variation of anterior belly described by De-Ary-Pires (8).

The clinical impact of these variations is associated with differential diagnosis between cervical masses found during surgery on the anterior neck and especially in submental and submandibular regions which results on the procedures of treatment and in radiology departments when asymmetry of the floor of the mouth is observed by different types of medical imaging (9, 10).

The described variations of accessory digastric bellies modify the standard topographic anatomy of the suprahyoid region and may therefore bear considerable significance in plastic and reconstructive surgery. Their impact is most essential in creation of myocutaneous flaps, in diagnostic approaches to submental lymphadenopathies such as lymph-node biopsy; and in emergency interventions in the submental and submandibular triangles of the neck (7, 11).

CONCLUSION

In summary, two cases of atypical and asymmetrical anterior bellies of digastric muscle with supernumerary muscle bundles in the submental region were described. The fact that two variations were found simultaneously on two separate cadavers and the embryological explanations in the literature support these findings makes them of extreme importance for the medical practice. The clinical specialists should be aware of such anatomical variants of the submental region during surgical procedures, imaging interpretation or differential diagnosis of neck masses.

REFERENCES

1. Reyes, G., Contreras, C., Ramírez, LM., Ballesteros, LE., The digastric muscle's anterior accessory belly: case report. *Med Oral Patol Oral Cir Bucal*, 12:341-343, 2007.
2. Standring, S., Gray's anatomy: The anatomical basis of clinical practice. 41st ed., Elsevier Limited, Philadelphia, p. 449, 2016.
3. Tubbs, RS., Shoja, MM., Loukas, M., Bergman's Comprehensive Encyclopedia of Human Anatomic Variation. Wiley-Blackwell, p. 228, 2016.
4. Kim, SD., Loukas, M., Anatomy and variations of digastric muscle. *Anat Cell Biol*, 52:1-11, 2019.
5. Hsiao, TH., Chang, HP., Anatomical variations in the digastric muscle. *Kaohsiung J Med Sci*, 35:83-86, 2019.
6. Kawai, K., Koizumi, M., Honma, S., Tokiyoshi, A., Kodama, K., Derivation of the anterior belly of the digastric muscle receiving twigs from the mylohyoid and facial nerves. *Ann Anat*, 185:85-89, 2003.
7. Natsis, K., Piagkou, M., Vrochidis, P., Papadopoulou, E., Lazaridis, N., Unilateral asymmetrical anterior bellies of the digastric muscle in coexistence with accessory muscle bundles in the submental triangle: A rare case report. *Morphologie*, 102:83-86, 2018.
8. De-Ary-Pires, B., Ary-Pires, R., Pires-Neto, MA., The human digastric muscle: patterns and variations with clinical and surgical correlations. *Ann Anat*, 185:471-479, 2003.
9. Liquidate, BM., Barros, MD., Alves, AL., Pereira, CSB., Anatomical Study of the Digastric Muscle: Variations in the Anterior Belly. *Int. J. Morphol*, 25:797-800, 2007.
10. Uzun, A., Aluclu, A., Kavakli, A., Bilateral accessory anterior bellies of the digastric muscle and review of the literature. *Auris Nasus Larynx*, 28:181-183, 2001.
11. Šink, Ž., Umek, N., Cvetko, E., Cross-over type of supernumerary digastric muscle: a case report. *Folia Morphol (Warsz)*, 78:647-650, 2019.