



*Original Contribution*

**STUDIES ON CLINICAL AND MORPHOLOGICAL EFFECTS OF ENZOOTIC ATAXIA ON KID GOATS**

**P. Petkov<sup>1</sup>, D. Kanakov<sup>1\*</sup>, R. Binev<sup>1</sup>, I. Dinev<sup>2</sup>, K. Kirov<sup>3</sup>, R. Todorov<sup>2</sup> and P. Petkova<sup>4</sup>**

<sup>1</sup>Department of Internal Medicine, Faculty of Veterinary Medicine, Trakia University, Stara Zagora, Bulgaria,

<sup>2</sup>Department of Pathological Anatomy,

<sup>3</sup>Central Laboratory of Veterinary Control and Ecology – Sofia,

<sup>4</sup>Veterinary student

**ABSTRACT**

This study was carried out on adult goats and their newborns (kid goats) obtained from different farms in same region of Bulgaria. The animals were divided into four groups: group I – kid goats with clinical signs of ataxia (n=12), group II – kid goats without these clinical signs (n=12), group III – dams of ataxia kid goats (n=6) and group IV - dams of healthy kid goats (n=6). The animals were subjected to full laboratory examinations for the following haematological parameters: haemoglobin (HGB), red blood cells count (RBC), white blood cells (WBC), mean cell volume (MCV), haematocrit (HCT) and differential white cells count. In addition the following mineral levels were measured in serum and liver tissues: Ca, Mg, Cu, Zn, Fe, and Se. We observed a fall in body temperature, an increase in heart and respiratory rates, a decrease of haemoglobin and red blood cells levels and changes in differential white cells count in positive cases of this disease. In addition, there were significant decreases in levels of Cu, Mg, Fe and Se. In liver tissues Cu levels were extremely low.

**Key words:** Kid goats, Hypocuprosis, Copper

**INTRODUCTION**

Copper is an essential component of several functions in animal metabolism (1, 2, 3, 4, 5) Ruminant Cu deficiency is of a pandemic nature but is more intense in regions where the pasture land is high in molybdenum (6, 7, 8, 9). Uncoordinated movement in the newborn ruminant has been recognized and given local names such as “swayback”, and “lamcruis”. All these conditions are pathologically identical results of a degeneration of the white matter of the cerebrum, and the name ‘enzootic neonatal ataxia’ can aptly be applied to them. In 1937 Bennetts and Chapman showed that ataxia of lambs occurring in Western Australia was associated with subnormal levels of copper in the pastures and, consequently, in the blood

and tissue of both ewes and affected lambs. This, they found, could be prevented by copper supplementation of the ewe during pregnancy. Enzootic ataxia had been described in the young of ruminants – cattle (calves) (1, 10, 11), sheep (lambs) (1, 3, 10, 12, 13), goat (kids) (2, 3, 4, 5, 6, 7, 10, 13, 14, 15, 16, 17, 18) and horses (1). Neonatal ataxia has been produced, under experimental conditions, by feeding ewes with diets deficient in copper made possible by high molybdenum and sulphate (8, 11, 19, 20). High lead intakes may sometimes be involved in the incidence of the condition because of the reciprocal antagonism at the absorptive level between Pb and Cu (17). Cu, Mo and sulphur could combine in the rumen to form an unabsorbable triple complex called copper thiomolybdate (Cu-TMs). The important physiological effect of Cu-TMs is to restrict the availability of Cu for ceruloplasmin synthesis (1, 9, 10, 11, 19, 20, 21, 22). Approximately 72-79% of the Cu is presented into liver tissue. Ruminants, especially sheep and goats, are much more susceptible to

\* **Correspondence to:** Dian T. Kanakov MD, The Thracian University, Faculty of Veterinary Medicine, Department of Internal Non-Infection Diseases; 6000 Srara Zagora, Bulgaria, Phone: +35942 699529, Fax: +35942 670624, Mobile: +359889 448081; E-mail [dian@gbg.bg](mailto:dian@gbg.bg)

Cu:Mo imbalance than are non-ruminant animals because of the sulphide generating bacteria in the rumens of the former (2, 10, 13, 14, 15, 16, 19, 20, 22). In lambs copper deficiency cause hypochromic and macrocytic anaemia (10). In this paper we described our investigations on an endemic cases of neonatal ataxia in lambs under field conditions.

## MATERIALS AND METHODS

### Animals

The kid goats were aged 0 to 8 weeks and had weight range of 2.5 to 6 kg. They were evenly distributed gender-wise (n=6). The adult goats were aged 2 to 4 years with weight range of 38 to 52 kg. The animals came from different farms in the Nova Zagora area of Bulgaria.

### Procedures

The animals were divided into 4 groups: group I – kid goats with clinical manifestation (n=12), group II – clinically healthy kid goats (n=12), group III – dams of the kid goats from group I (n=6) and group IV –dams of the kid goats from group II (n=6). All animals underwent routine tests for body temperature (rectal), heart rate, respiratory rate, mucus colour, appetite, thirst, general behaviour, movement, sensitivity, urine, faeces etc. Blood samples were taken from v. jugulars for determination of haemoglobin (Hgb), red blood cells (RBC) white blood cells (WBC), haematocrit (HCT), mean cells volume (MCV) with automatic haeme analysis, (Serono+System 150, USA) and differential blood count (by Pappenheim).

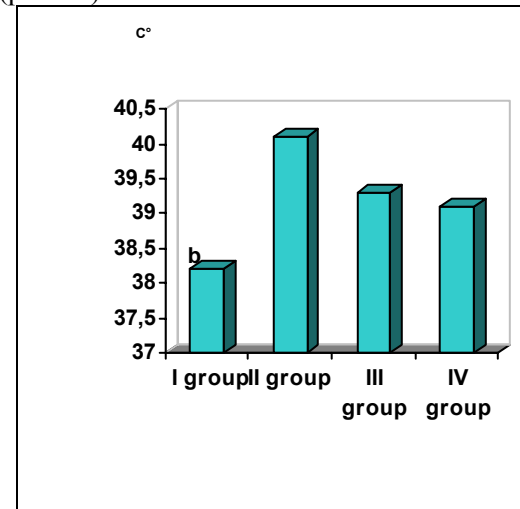
Serum levels of the elements Ca, Mg, Cu, Zn, Fe and Se were determined. Five of the kid goats with severe clinical symptoms were subjected to euthanasia for a complete necropsy. Liver tissue samples were taken from all of them for a mineral analysis of the same elements. The analyses were performed in Central Laboratory of Veterinary Control and Ecology – Sofia by atom-absorption spectrophotometer AAES Variant 5120.

### Statistical analyses

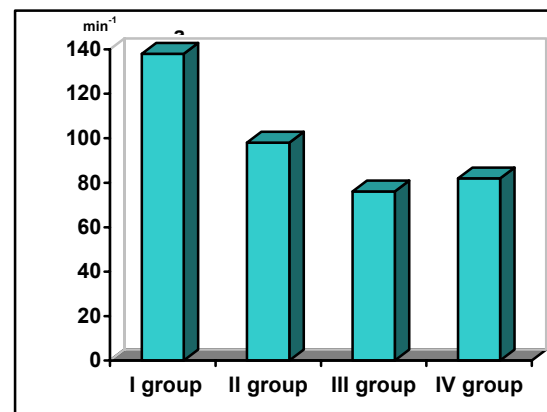
For determination of the rate of significance of experimental results we used t-test of Student-Fisher. Statistical significance of the differences between mean levels for the control and experimental groups were calculated. Statistical reliability was fixed at  $p < 0.05$ .

## RESULTS

Examination of body temperature (**Figure 1**) showed decrease of this parameter in kid goats with clinical manifestation (group I). The temperature was  $38.2 \pm 0.4^\circ\text{C}$ ; the group of clinically healthy kids (group II) -  $40.1 \pm 0.3^\circ\text{C}$  ( $p < 0.01$ ).



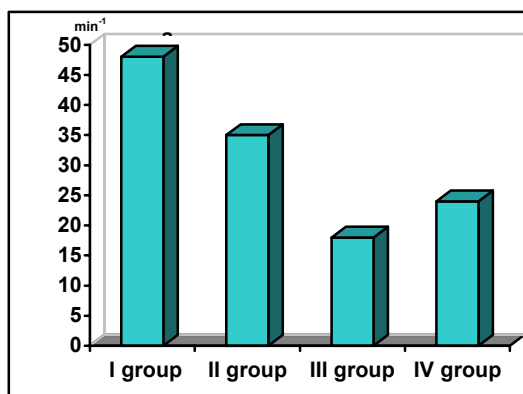
**Figure 1.** Changes in body temperature in kid goats with enzootic ataxia (I group), healthy kid goats (II group), dams of kid goats with enzootic ataxia (III group), dams of healthy kid goats (IV group). Levels of significance vs. controls:  $^a p < 0.05$ ;  $^b p < 0.01$ ;  $^c p < 0.001$



**Figure 2.** Changes in heart rate in kid goats with enzootic ataxia (I group), healthy kid goats (II group), dams of kid goats with enzootic ataxia (III group), dams of healthy kid goats (IV group). Levels of significance vs. controls:  $^a p < 0.05$ ;  $^b p < 0.01$ ;  $^c p < 0.001$

The heart rate (**Figure 2**) of the kid goats with enzootic ataxia (group I) was significantly increased ( $138 \pm 14 \text{ min}^{-1}$ ) relative to the clinically healthy animals -  $98 \pm 11 \text{ min}^{-1}$  ( $p < 0.05$ ). Similarly, there was increased respiratory rate (**Figure 3**). This was significantly different in animals with ataxia -  $48 \pm 8 \text{ min}^{-1}$ , compared to healthy kid goats -  $36 \pm 6 \text{ min}^{-1}$  ( $p < 0.05$ ). In addition, the following changes were observed: loss of

muscular coordination leading to uncoordinated movements, paresis of the hind legs, impossibility to suckle, spasmodic contraction, generalised tremor and convulsions. In two of the kid goats, unilateral blindness due to the turbidity of the cornea was observed. Dams of the defective kid goats did not show any changes in clinical stature. Haematological examinations (**Table 1**) showed great differences. Haemoglobin levels of the kid goats with ataxia were decreased:  $81.2 \pm 3.8$  g/l versus the levels of same indicator for the clinically healthy animals -  $144.6 \pm 5.2$  g/l ( $p < 0.001$ ). Red blood cells count in defective animals were materially lower -  $7.15 \pm 1.17$  T/l compared to the animals without symptoms of the -  $15.12 \pm 1.68$  T/l ( $p < 0.01$ ). Higher values for white blood cells count in the kid goats with ataxia -  $22.16 \pm 0.8$  G/l, against the healthy kid goats  $10.12 \pm 0.7$  G/l ( $p < 0.001$ ) were established. The haematocrit was changed.



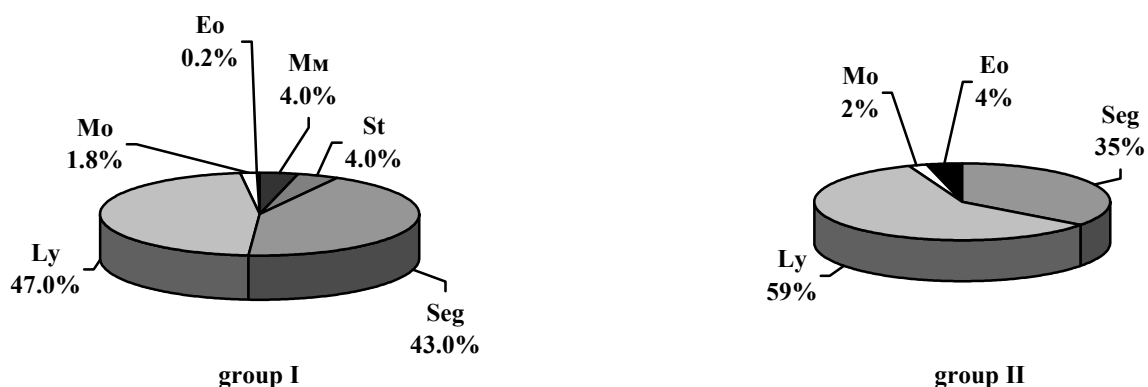
**Figure 3.** Changes in respiratory rate in kid goats with enzootic ataxia (I group), healthy kid goats (II group), dams of kid goats with enzootic ataxia (III group), dams of healthy kid goats (IV group). Levels of significance vs. controls: <sup>a</sup> $p < 0.05$ ; <sup>b</sup> $p < 0.01$ ; <sup>c</sup> $p < 0.001$

Data for the haematological

examinations in goats from the groups III and IV showed changes in haemoglobin levels only. Haemoglobin levels in dams of the kid goats with ataxia were lower -  $93.3 \pm 4.2$  g/l, than the levels in dams of the healthy kid goats -  $128.6 \pm 4.5$  g/l ( $p < 0.001$ ). The other indicators (red blood cells, white blood cells, haematocrit) changed slightly. The results for percentage proportion of the different white blood cell classes (**Figure 4**) in kid goats with enzootic ataxia and clinically healthy kid goats showed changes expressed as: decrease of the eosinophils (Eo) -  $0.2 \pm 0.2\%$ , versus -  $4.0 \pm 1\%$  ( $p < 0.01$ ), increase of the adult neutrophils (Sg) -  $43.0 \pm 2.0\%$ , versus -  $37.0 \pm 1.9\%$  ( $p < 0.05$ ) and decrease of the lymphocytes (Ly) respectively -  $47.0 \pm 2.3\%$ , versus -  $62.0 \pm 3.5\%$  ( $p < 0.01$ ). In the blood of the kid goats with ataxia were found metamyelocytes (Mm) -  $4.0 \pm 1.0\%$  and band neutrophils -  $4.0 \pm 0.2\%$ , not detected in healthy animals.

Mineral analysis of the blood serum showed significant decrease in serum Cu levels for the group I -  $0.92 \pm 0.23$  ppm compared to the level for group II -  $2.17 \pm 0.53$  ppm ( $p < 0.001$ ). Serum iron (Fe) levels for clinically defective kid goats were  $1.15 \pm 0.34$  ppm, while for healthy kid goats -  $3.64 \pm 1.31$  ppm ( $p < 0.001$ ). An increase was found in Mg serum levels of the defective animals  $6.54 \pm 2.89$  against  $10.71 \pm 1.24$  ppm for group II and in Se serum levels respectively  $0.091 \pm 0.009$  ppm and  $0.148 \pm 0.009$  ppm ( $p < 0.01$ ). Significant differences between groups III and IV in serum mineral levels were measured only for Cu:  $1.17 \pm 0.22$  ppm for group III in comparison to  $1.64 \pm 0.22$  ppm for group IV.

**Figure 4.** Changes in differential leukocyte counts in kid goats with enzootic ataxia (group I), healthy kid goats (group II)



**Table 1.** Haematological parameters in kid goats with enzootic ataxia (I group), healthy kid goats (II group), dams of kids with enzootic ataxia (III group), dams of healthy kid goats (IV group). Levels of significance v controls: <sup>a</sup>p<0.05; <sup>b</sup>p<0.01; <sup>c</sup>p<0.001

Group	Hemoglobin (g/l)	Erythrocytes (T/l)	Leucocytes (G/l)	Hematocrit (%)
I	81.2±3.8 <sup>c</sup>	7.2±1.2 <sup>b</sup>	23.2±0.8 <sup>c</sup>	29.9±3.2
II	144.6±5.2	15.1±1.7	10.1±0.7	32.3±4.4
III	93.3±4.2 <sup>c</sup>	13.6±1.2	12.3±1.4	37.6±3.8
IV	128.6±4.5	14.1±2.1	11.4±1.8	33.2±5.2

Mineral examinations of liver tissue showed Cu levels of 17.97±7.86ppm (n=5), compared to the normal levels for this element in newborn small ruminants 75÷430ppm (17). Individual level was extremely low - 9.82ppm.

## DISCUSSION

The clinical symptoms of hypothermia, tachycardia and increase in respiratory rate in kid goats with enzootic ataxia were observed. The hypothermia could have occurred as a result of morphological changes in brain substance thus giving rise to thermoregulatory mechanism disturbance (7, 16). The increase in respiratory rate and tachycardia may be compensation of registered decrease of haemoglobin levels and erythropenia in kid goats with enzootic ataxia (6). Demonstrated heart muscle degeneration complements the mechanism of tachycardia (5).

Our observations of the following clinical symptoms, suckling difficulties, tremor, spasmodic contraction, generalized convulsions, loss of muscular coordination, uncoordinated movements, paresis of the hind legs, blindness etc, confirm previous findings (4, 6, 17, 18) related to morphological changes in the cerebrum (3, 7, 15). The decrease of haemoglobin levels and erythropenia may be due to the influence of copper deficiency on haemosynthesis (9, 10, 14).

Regenerative leucocytosis with neutrophilia is related to observed inflammatory changes in the parenchyma organs (3, 7, 15, 16).

## CONCLUSION

1. Enzootic ataxia in the kid goat affects animals in the age range of 0 to 8 weeks, male and female and occurs in an endemic form.
2. Clinical signs are hypothermia, tachycardia and increase in respiratory rate, paresis,

tremor, convulsions, contractions and blindness.

3. Haematological changes express a decrease of haemoglobin levels, erythropenia and regenerative leucocytosis with neutrophilia.
4. Liver and serum copper levels are extremely low.
5. Dams of the kids with enzootic ataxia are clinically healthy, but with low levels of haemoglobin and serum copper.

## REFERENCES

1. Ladefoged, O., Stürup, S., 1995. Copper deficiency in cattle, sheep and horses caused by excess molybdenum from fly ash: A case report. *Veterinary and Human Toxicology*, 37, 63–65.
2. Osman, N. I. E. D., Johnson, H., Al-Busaidi, R. M., Suttle, N. F., 2003. The Effects of Breed, Neonatal Age and Pregnancy on the Plasma Copper Status of Goats in Oman. *Veterinary Research Communications* 27, 3, 219 – 229.
3. Roeder, P. L., 1980. Enzootic ataxia of lambs and kids in the Ethiopian Rift Valley. *Trop Animal Health Prod.*, 12, 4, 229-233.
4. von Beust, B. R., Vandavelde, M., Tontis, A., Spichtig, M., 1983. Enzootic ataxia of kid goats in Switzerland Schweiz Arch Tierheilkd., 125, 6, 345-351.
5. Wouda, W., Borst, G. H., Gruys, E., 1986. Delayed swayback in goat kids, a study of 23 cases. *Vet Q.*, 8, 1, 45-56.
6. Banton, M. I., Lozano-Alarcon, F., Nicholson, S. S., Jowett, P. L., Fletcher, J., Olcott, B. M., 1990. Enzootic ataxia in Louisiana goat kids. *J Vet Diagn. Invest.*, 2, 1, 70-73.
7. Cordy, D. R., Knight, H. D., 1978. California goats with a disease resembling enzootic ataxia or swayback. *Vet Pathol.*, 15, 2, 179-185.
8. Mason, J., 1990. The biochemical pathogenesis of molybdenum-induced copper deficiency syndromes in ruminants:

- Towards the final chapter. *Irish Veterinary Journal*, 43, 18 – 21.
9. Suttle, N. F., 1974. Recent studies of the copper-molybdenum antagonist. *Proceeding Nutrition Society*, 33, 299–305.
  10. Gooneratne, S. R., Buckley, W. T., Christensen, D. A. 1989. Review of copper deficiency and metabolism in ruminants. *Canadian Journal Animal Science*, 69, 819-845.
  11. Ward, J. D., Spears, J. W., Kegley, E. B., 1993. Effect of copper level and source (copper lysine vs copper sulphate) on copper status, performance, and immune response in growing steers fed diets with or without supplemental molybdenum and sulphur. *Journal Animal Science*, 71, 2748-2754.
  12. Hooper, P. T., 1975. Original Investigations Spongy degeneration in the central nervous system of domestic animals *Acta Neuropathologica (Historical Archive) Part I: Morphology*, 31, 4, 325 – 334.
  13. Ivan, M., Hidioglou, M., al-Ismaily, S. I., al-Sumry, H. S., Harper, R. B., 1990. Copper deficiency and posterior paralysis (Shalal) in small ruminants in the Sultanate of Oman. *Trop. Anim. Health Prod.*, 22, 4, 217-225.
  14. Draksler, D., Nunez, M., Apella, M. C., Agüero, G., Gonzalez, S., 2002. Copper deficiency in Creole goat kids *Reprod. Nutr. Dev.*, 42, 2002, 243-249
  15. Hartley, W. J., Clarkson, D. J., 1989. An outbreak of spinal neuronopathy of goat kids in Fiji. *New Zealand Veterinary Journal*, 37, 4, 158-159.
  16. Lofstedt, J., Jakowski, R., Sharko, P., 1988. Enzootic ataxia and caprine arthritis/encephalitis virus infection in a New England goatherd [corrected *J Am Vet Med Assoc.*, 193, 10, 1295-1298.
  17. O'Sullivan, B., M., 1977. Enzootic ataxia in goat kids. *Aust Vet J.*, 53, 9, 455-456.
  18. Seaman, J. T., Hartley, W. J., 1981. Congenital copper deficiency in goats. *Aust Vet J.*, 57, 7, 355-356.
  19. Suttle, N. F., 1991. The interactions between copper, molybdenum, and sulphur in ruminant nutrition. *Annual Veterinary Nutrition*, 11, 121–140.
  20. Wittenberg, K. M., Boila, R. J., 1988. Supplementary copper for growing cattle consuming diets high in molybdenum or molybdenum plus sulphur. *Canadian Journal Animal Science*, 68, 1143–1154.
  21. Dick, A. T., Dewey, D. W., Gawthorne, J. M., 1975. Thiomolybdates and the copper – molybdenum – sulphur interaction in ruminant nutrition. *Journal Agricultural Science*, 85, 567 –568.
  22. Ward, J. D., Gengelbach, G. P., Spears, J. W., 1997. The effects of copper deficiency with or without high dietary iron or molybdenum on immune function of cattle. *Journal Animal Science*, 75, 1400-1408.