



### Case Report

## AN INCALCITRANT SYMPTOMATIC PAEDIATRIC CLOSED TIBIAL MEDIAL MALLEOLUS FRACTURE (CASE REPORT)

T. Al-Sadek<sup>1\*</sup>, F.Yu-Sing Chan<sup>2</sup>, A. Al-Sadek<sup>3</sup>, G. Dimitrov<sup>4</sup>, K. Marinov<sup>5</sup>

<sup>1</sup>Department of Orthopaedics and Traumatology, Belhoul European Hospital, Dubai, UAE

<sup>2</sup>Tameside Hospital NHS, Foundation Trust, Manchester, UK

<sup>3</sup>Medical University, Sofia, Bulgaria

<sup>4</sup>Department of Orthopaedics and Traumatology, Medical University, Pleven, Bulgaria

<sup>5</sup>Department of Special Surgery /Thoracic Surgery, Vascular Surgery, Pediatric Surgery and Orthopaedics and Traumatology, University Hospital "Prof. Dr. St. Kirkovich", Stara Zagora, Bulgaria

### ABSTRACT

**Purpose:** In this study, we reported a rare paediatric closed medial malleolus fracture non-union (the fracture did not involve the growth plate).

**Methods:** The fracture was initially treated with Plaster-of-Paris cast for 6 weeks followed by physiotherapy. The fracture position and union were assessed regularly with X-rays.

Open reduction and internal fixation with cannulated screw was performed. Intraoperatively, there were only minimal soft tissues in the fracture gap and they were cleared prior to fixation. Further regular X-rays suggested fracture position was maintained but lack of callus formation. The patients remained symptomatic. A few months following the operation, the non-invasive ultrasound bone stimulator treatment was arranged for six months in view of the non-union. On completion of the treatment, she remained painful on weight-bearing. Subsequently radiological investigations confirmed fracture non-union. Further open reduction internal fixation with autologous bone-grafting was performed.

**Results:** The fracture was finally united a few months following the autologous bone-grafting procedure and the patient's symptoms resolved. The fracture was also confirmed to be united radiologically.

**Conclusion:** In this study, we reported one of these rare closed symptomatic medial malleolus non-union without growth plate involved. While following multiple treatment modalities (both conservative & invasive), fracture union was finally achieved. The union occurred over more than a year period.

**Key words:** Incalcitrant, Paediatric, Closed, Tibial, Medial, Malleolus, Fracture.

### INTRODUCTION

While closed ankle fractures are common in paediatric trauma (recent epidemiological studies suggests over seventy percent have malleolus fracture and the lateral malleolus is the most commonly involved). With the increased vascularity of the children growing bone, the traditional wisdom informs us that paediatric ankle fracture non-union is extremely uncommon especially in a closed fracture (recent studies suggests medial malleolus fracture accounts for less than 7% of paediatric non-union).

While the studies suggest 18% of paediatric non-union are asymptomatic, all medial malleolus non-union in the studies are

symptomatic requiring further treatment(s). The medial malleolus fracture can be subdivided by whether the fracture involved the tibial growth plate or not. The traditional wisdom suggests that delayed union or non-union is more likely when the growth plate is disturbed by the fracture. Nonetheless, very little is known or published on the optimal treatment of this rare but problematic medial malleolus fractures non-union.

In this study, we reported a rare paediatric closed medial malleolus fracture non-union (the fracture did not involve the growth plate).

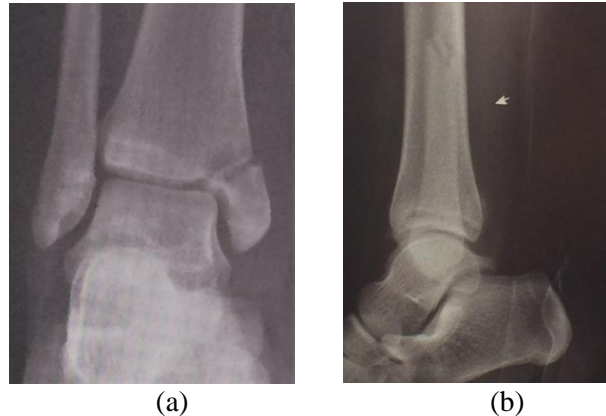
### CASE PRESENTATION

A 14 years old girl was involved in a road traffic accident as a pedestrian. She was hit at the side of her knee by a car and thrown over. She then landed on her ankle. She was taken

\*Correspondence to: *Tabet Al-Sadek, M.D, Ph.D, Belhoul European Hospital, Dubai-UAE. Email: drthabet@abv.bg; Mobile: +971551503964*

by the ambulance to the Emergency Department and the ankle X-ray revealed minimally displaced closed ankle medial

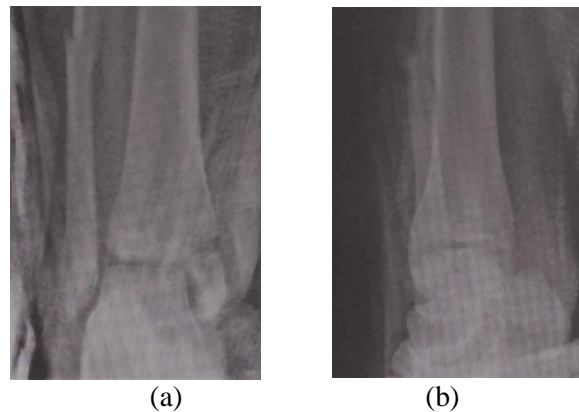
malleolus with distal fibula fracture (**Figure 1**). She was hospitalised and no other injury was identified.



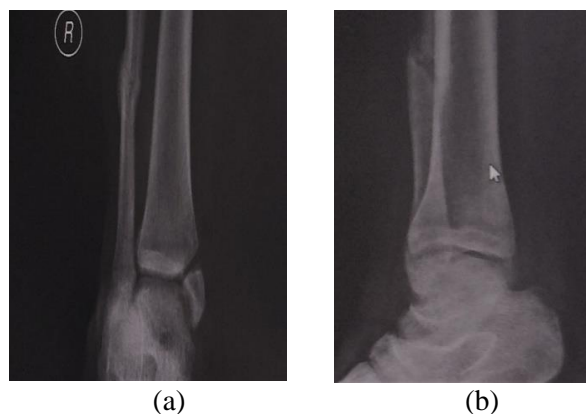
**Figure 1.** a- AP view of Pre- cast X-ray, b- Lateral view of Pre-cast X-ray. (Diagnostic AP and Lateral X-rays).

The fracture was initially treated with Plaster-of-Paris cast for 6 weeks followed by physiotherapy. The fracture position and union were assessed regularly with X-rays (**Figure 2**). Despite the above measure, she remains

painful on weight-bearing and X-rays revealed uneventful union of the distal fibula fracture but persisting visible medial malleolus fracture line with no/ minimal callus formation (**Figure 3**).



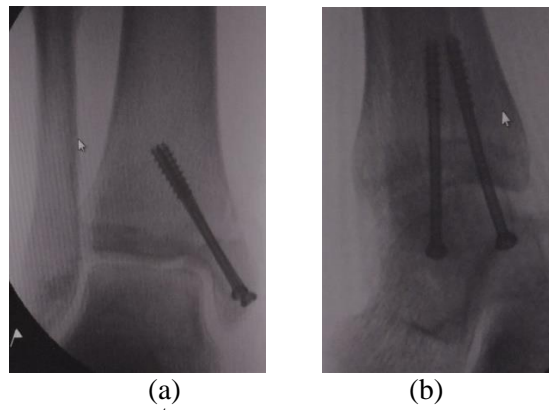
**Figure 2.** a- AP view of immediate Post-Cast X-ray. , b- Lateral view of immediate Post-Cast X-ray.



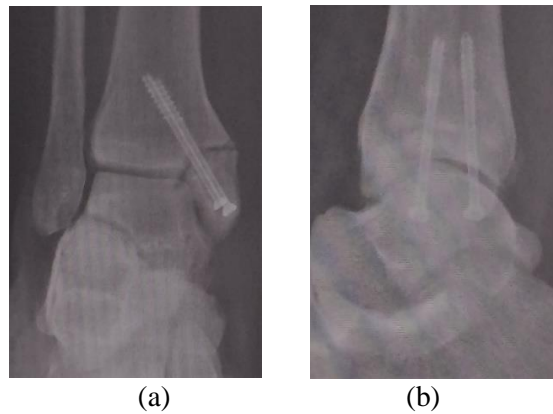
**Figure 3.** a- AP view of X-ray after 6 months. , b- Lateral view of X-ray after 6 months.

Open reduction and internal fixation with cannulated screw was performed. Intraoperatively, there were only minimal soft tissues in the fracture gap and they were cleared prior to fixation (**Figure 4**). Further regular X-rays suggested fracture position was maintained but lack of callus formation (**Figure 5**). The patients remained

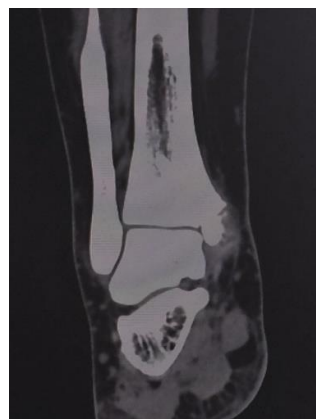symptomatic. A few months following the operation, the non-invasive ultrasound bone stimulator treatment was arranged for six months in view of the non-union. On completion of the treatment, she remained painful on weight-bearing. Subsequently radiological investigations (CT Scan) confirmed fracture non-union (**Figure 6**).



**Figure 4.** a- AP view Intraoperative 1<sup>st</sup> ORIF X-ray. b- Lateral view Intraoperative 1<sup>st</sup> ORIF X-ray.



**Figure 5.** a- AP view 14 months post injury X-ray. b- Lateral view 14 months post injury X-ray.

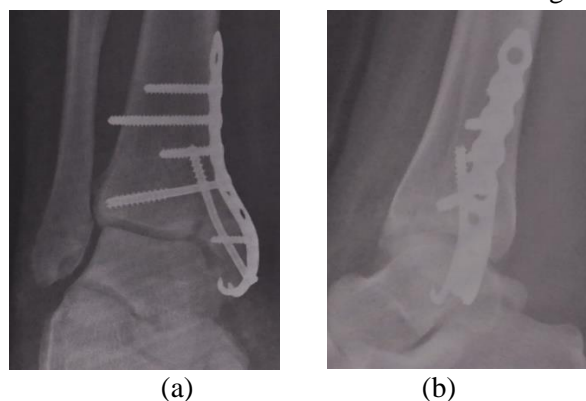


**Figure 6.** CT scan confirming non-union.

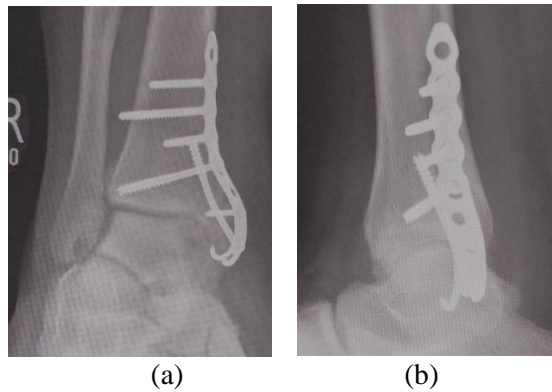
Further open reduction internal fixation with autologous bone-grafting was performed (**Figure 7**).

## RESULTS

The fracture was finally united a few months following the autologous bone-grafting procedure and the patient's symptoms resolved. The fracture was also confirmed to be united radiologically (**Figure 8**).



**Figure 7.** a- AP view Post Bone-Grafting X-ray. b- Lateral view Post Bone-Grafting X-ray.



**Figure 8.** a- AP view final X-ray. b- Lateral view final X-ray.

## DISCUSSION

With increased vascularity of children's bone, it is claimed that fracture mal-union is more common with non-union being rare. In this study, we reported one of these rare closed symptomatic medial malleolus non-union without growth plate involved. While following multiple treatment modalities (both conservative & invasive), fracture union was finally achieved. The union occurred over more than a year period. The damaging effects of this period to the child's psychological, educational & physical developments should not be underestimated. The repeated radiological investigations both during and

following the treatments (to assess growth disturbance) is also potentially harmful.

Further studies on the optimal treatment protocol of this fracture non-union would be highly recommended to minimise the above harms.

## REFERENCES

1. Shrader MW, Stans AA, Shaughnessy WJ, Haidukewych GJ. Nonunion of Fractures in Pediatric Patients: 15-Year Experience at a Level I Trauma Center. *Orthopedics*. June; 32(6):410, 2009.