



Review

USING OF TRANSULCAL MICROSURGICAL APPROACH IN SURGICAL TREATMENT OF INTRACEREBRAL LESIONS - LITERATURE REVIEW

St. Valkanov*, P. Valkanov

Clinic of Neurosurgery at Stara Zagora University Hospital, Trakia University, Stara Zagora, Bulgaria

ABSTRACT

The surgical resection of intracerebral lesions, and particularly those in the dominant hemisphere, is often a challenge. Standard approaches require significant brain retraction or resection of normal neural tissue. However, the type of surgical approach affects on the postoperative recovery and complications. The introduction of the microsurgery and computer-led stereotactic laser resection, neuronavigation, brain mapping – all these methods which allows a complete resection and sparing of the surrounding normal neural tissue, improves the results and the pursuit of atraumatic neurosurgical operations. Our goal was to make a literature review on application of trans-sulcal microsurgical approach by other authors, since its introduction in the microneurosurgery practice by Prof. G.Yasargil in 1986. It is a minimally invasive technique that is relatively simple and provides additional accuracy and safety of the surgical procedure. It ensures less traumatic surgical interventions and preserves as much as possible the physiological and anatomical structures of the cerebrum.

Key words: trans-sulcal microsurgical approach, minimally invasive brain surgery

Ever since its introduction in 1965 by Prof. G. Yasargil, microneurosurgery goes deeply into all sections of neurosurgical practice and gives the opportunity many new surgical methods to be introduced, while many of the old ones to be improved and be carried out with greater certainty and atraumacity. On the other hand, the entry into the daily practice of less invasive and aggressive but more accurate diagnostics (CT, MRI, PET), which can accurately depict pathoanatomical and pathophysiological characteristics of the lesion, facilitates the diagnosis of small asymptomatic lesions located in the deep parts of the brain hemispheres. That is how appears the need of using new, improved surgical techniques with which these lesions can be achieved with minimal damage to the cortex. Trans-sulcal microsurgical approach is based on the idea that the less is the damage to the cerebral cortex and white matter, the less damage is caused to the patient by the surgeon (1).

In 1986 G.Yasargil indicates that there are no “silent areas” in the brain. All areas are eloquent

and each has its own unique function. They are all intricately interwoven and integrated into a dynamic unity. Here he brings the idea of respect for a basic surgical principle those natural anatomic routes (cisternal, sulcal, fissural, ventricular) can be used to reach deep localized tumors and perform a pure “tumorctomy” “thereby avoiding compression or resection of normal neural tissue (2). It also gives a schematic representation of a sulcal and fissure structures available in front of and behind bauricular line (**Figures 1 and 2**).

In 1989, Harkey HL et al presents an anatomical study of cerebral sulci on a cadaver brains which were dissected using operative microscope, photographed for surface mapping and X-ray examinations were done to demonstrate the underlying ventricular relationships between deep brain structures and the sulci. By sectioning in the coronal plane was shown the relationship between the sulci and deep brain structures. They identified three important sulci, which were detail described as well as their relation to the surface, average depth and related structures that can be easily reached. The authors discuss the surgical application of these findings, and concluded that the trans-sulcal approach to

*Correspondence to: St. Valkanov, Clinic of Neurosurgery, University Hospital, Stara Zagora, Bulgaria, nhk_stz@yahoo.com

intraventricular and intra-axial lesions avoids great damage to brain tissue, so as it is by using a conventional cortical section (3).

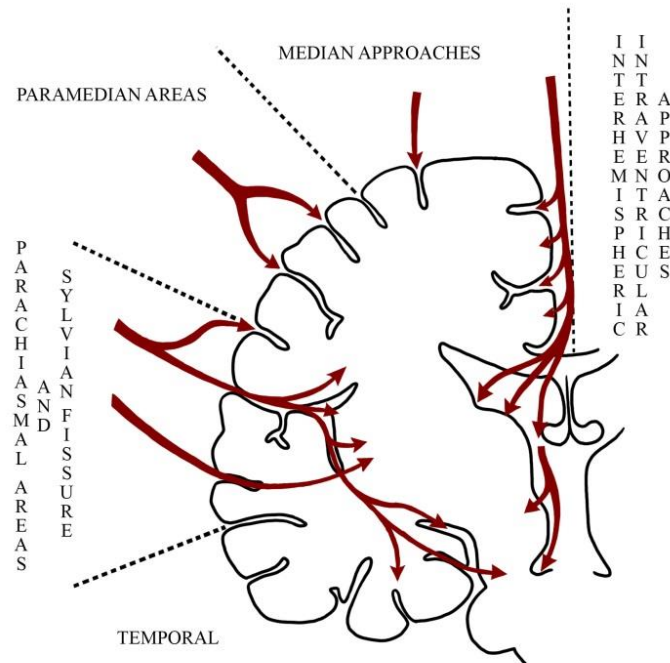


Figure 1. Sulcal and fissural approaches to structures which are anterior to bicaudal line (by Yasargil).

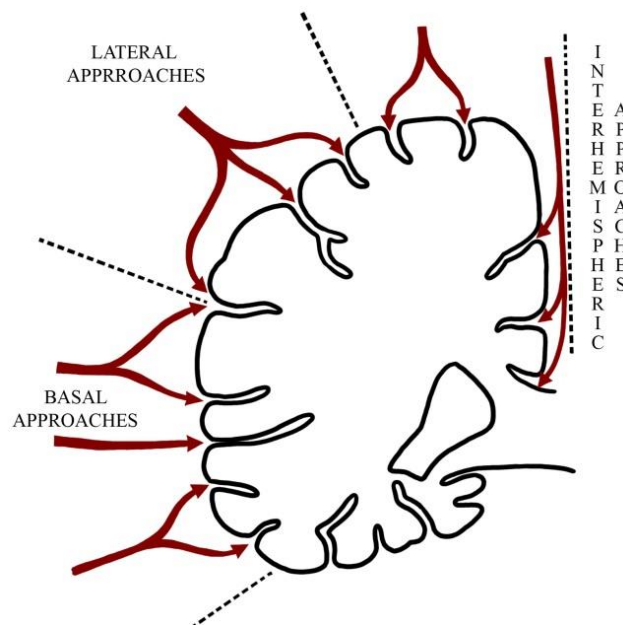


Figure 2. Sulcal and fissural approaches to structures posterior to the bicaudal line (by Yasargil).

In 1991. Garcia Sola R, Pulido P. and Kusak E. used combined stereotactic-microsurgical approach, mainly for the removal of small subcortical lesions, determining their location and the path to be followed. They reported 20 cases (1 AVM, 12 tumor lesions, 1 abscess and 6 hematomas) in which they systematically applied a dissection of the cisterns or sulci to reach the

lesion, which was previously proposed by Yasargil, in order to reach the disease process with minimal or no damage to normal neuroanatomy. Finally, they noted that transsulcal approach is convenient because of the less discomfort for the patient, the smaller brain parenchyma injury (4).

In 1994. Kunz et al reported the experience of 7 cases of patients with cavernous hemangioma operated by stereotaxically and ultrasound guided trans-sulcal microsurgical access. The authors do not established postoperative neurological deficit, although in 6 of 7 patients, the tumors were in functional areas. They attributed the low percentage of complications in operated patients group, of exact preoperative localization, which helps to avoid major trauma on normal brain tissue, attach importance to the successful combination of stereotaxic system and ultrasonic guided trans-sulcal approach and describe the used technique as relatively simple and safe minimally invasive method (5).

In 1995. Ebeling et al concluded that stereotaxically-led microsurgery combined with trans-sulcal microsurgical access allows safe resection for small or deep-seated brain lesions without postoperative deficit in their series (6).

M. Germano in 1996 describes the use of trans-sulcal approach in the surgical treatment of mesiotemporal lesions, noting that the resection of these lesions, particularly those in the dominant hemisphere is often a challenge, and standard approaches require excessive retraction of the brain, removal of normal neural tissue, as well as manipulations of the middle cerebral artery branches. The author describes 3 cases, reaching the conclusion that the exact and precise knowledge of the temporal anatomical landmarks allows to achieve these lesions

without the navigational system, and the approach is appropriate in patients without neurological deficit (7).

In 1997. K. Matsumoto et al presents their experience in using trans-sulcal approach in the surgical treatment of intraventricular tumors of the trigonum. The author notes that the approach to the trigone of the lateral ventricle remains controversial because conventional accesses to these lesions sometimes cause neurological deficit. Incision of the superior parietal lobe is most used, since it avoids the visual pathway and speech and sensorimotor areas, but even the use of this approach may lead to a brain injury, because the pathway to the trigonum is too long. In order to minimize the force of retraction, the authors used trans-sulcal approach with excellent results. Finally they noted that this approach provides a less invasive access to the trigonum of the lateral ventricle (8).

In 1998. Karagiozov et al in "Atlas Of Neurosurgery" describes the microsurgical technique trans-sulcal access through the upper frontal sulcus in ventricular lesions, and also trans-sulcal approach through superior temporal sulcus in lesions of the temporal lobe. In the same neurosurgical atlas the authors recommends that the penetration to the metastatic brain lesions must be in the depth of the sulcus and says that there are some preferred places to penetrate brain hemisphere, using certain sulci in their depth (9) (**Figure 3**).

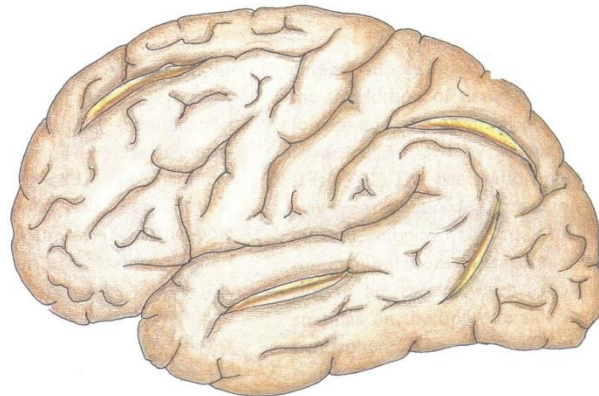


Figure 3. Most commonly used sulci for entry deep parts of brain hemispheres (by Karagiosov L.).

In 2002. R. Ramamurthi and K.Sridhar recommended that the entry through the sulcus to be performed only in the absence of large

veins in it, and also if the lesion is near the bottom of the sulcus.

Depending on the location of the lesion it is necessary to consider whether it is required to reach the bottom of the sulcus, or it is more direct to enter through one of the sulcal walls. The author describes the whole trans-sulcal approach in details, noting that it is safe and minimally invasive method.

In 2005. A. Jabre stated that it was useful to work through the cortical sulci, as conventional approaches require potential cortical dissection that leads to traumatic injuries of the surrounding parenchyma. He uses a frameless stereotaxy for localization of the lesion (subcortical cavernous angioma) and also for locating the nearest sulcus through which the lesion can be safely reached and removed. After reaching the bottom of the sulcus, a limited leukotomy was performed to expose and totally resect the cavernous angioma. In conclusion, the author notes that this minimally invasive technique, targeting both the adjacent sulcus and the lesion, is relatively simple and provides added accuracy and safety to the surgical procedure (10).

The same year, Nagata S. and Sasaki T. presents the lateral trans-sulcal approach to the treatment of asymptomatic trigonal meningiomas. The approach is studied on two cadaver brains and three patients with asymptomatic trigonal meningiomas. They opened the posterior part of Sylvian fissure or superior temporal sulcus to its bottom. The trigone of the lateral ventricle was exposed in the shortest distance by a small horizontal cortical incision trigone of the lateral ventricle. The meningiomas were detached from the choroid plexus and then removed. Although there is a potential risk of damage to the association fibers, radiatio opticus, the transverse gyrus of Heschl and parietal lobe, in-depth knowledge of the topographical anatomy and careful dissection technique can avoid operational injuries. The authors said that the wide opening of the Sylvian fissure and debulking of the tumor are other important factors to reduce the retraction of the parietal and temporal lobes (11).

L. Wang et al retrospectively studied 41 patients with lesions of the septum pellucidum, comparing and analyzing statistically the therapeutic effect, extends of tumor, and resection of normal brain tissue after the application of frontal transcortical, transsulcal and interhemispheric transcallosal approaches. They concluded that trans-sulcal and

transcallosal approaches are fit with the concept of minimally invasive surgery (12).

In 2006. Ribas E. et al reported that brain sulci constitute the main microanatomic delimiting landmarks and surgical corridors of modern microneurosurgery. Due to the frequent difficulties in intraoperative localization and visual identification of brain sulci with assurance, the authors doing a study which main purpose was to establish cortical - sulcal key points that are essential in microneurosurgical aspect and to provide a sulcal anatomic framework for precise localization of the craniotomies over the process and to facilitate intraoperative identification of the main sulci (13).

In 2008, Kaya A.H. et al used a stereotactic localization with a frame for reaching small subcortical lesions, noting that this method facilitates trans-sulcal approach to these lesions (14).

In 2010, Daglioglu E. et al noted that more than two-thirds of the cerebral cavernomas are located supratentorially and trans-sulcal approach without excision of the peritumoral parenchyma and simple tumorectomy are the keys to surgery on eloquent areas (15).

This overview of the literature indicates that surgical resection of intracerebral lesions, and particularly those in the dominant hemisphere, is often a challenge. Standard approaches require significant brain retraction or resection of normal neural tissue. However, the type of surgical approach affects on the postoperative recovery and complications. The introduction of the microsurgery and computer-led stereotactic laser resection, neuronavigation, brain mapping – all these methods which allows a complete resection and sparing of the surrounding normal neural tissue, even in the basal ganglia and thalamus, improves the results and the pursuit of atraumatic neurosurgical operations (16). Trans-sulcal microsurgical approach is a minimally invasive technique that is relatively simple and provides additional accuracy and safety of the surgical procedure (10). It should be recommended especially when working in the dominant brain hemisphere, to avoid disturbances in higher cognitive functions. Its use requires in-depth knowledge of microanatomy of the operative field, and knowledge of the existing anatomical markers,

for selecting an appropriate sulcus to access the lesion (7, 17, 18, 19).

REFERENCES

1. Sridhar, K. Is microsurgery required in every case of intraparenchymal Glioma? Singh AK (Ed) Indian Clinical Neurosurgery, CBS Publishers, 143-48, 2002.
2. Yasargil MG. "Microneurosurgery of CNS Tumors", IV B New York: Thieme Medical Publishers Inc.; p 91, 1996.
3. Harkey, HL., al-Mefty, O., Haines, DE., Smith, RR. The surgical anatomy of the cerebral sulci. *Chin Med J (Engl)*, May 20;118(10): 812-6, 2005.
4. Garcia Sola, R., Pulido, P., Kusak, E. Transfissural or trans-sulcal approach versus combined stereotactic-microsurgical approach. *Acta Neurochir Suppl (Wien)*, 52: 22-5, 1991.
5. Kunz, U., Goldmann, A., Bader, C., Oldenkott, P. Stereotactic and ultrasound guided minimal invasive surgery of subcortical cavernomas. *Minimally Invasive Neurosurgery*, Vol 37, Iss 1, p 17-20, 1994.
6. Ebeling, U., Hasdemir, M.G., Barth, A. Stereotaxy-guided microsurgery of cerebral lesions. *Minim Invasive Neurosurg.*, Mar;38(1): 10-5, 1995.
7. Germano, IM. Transsulcal approach to mesiotemporal lesions. Anatomy, technique, and report of three cases. *Neurosurg Focus*, 5: 1 – 8, 1996.
8. Matsumoto, K., Touho, H., Morisako, T., Karasawa, J., Ueda, S. Transsulcal approach to intraventricular tumor of the trigonum: Technical note. *Japanese Journal of Neurosurgery*, Vol 6, Iss 2, 134-136, 1997.
9. Karaguiosov, L., Ramadan, A., Karaguiozov, K. "Atlas of Neurosurgery", Kuwait, 149-161, 1998.
10. Jabre, A., Patel, A. Transsulcal microsurgical approach for subcortical small brain lesions: technical note. *Surgical Neurology* 65, 312–314, 2006.
11. Nagata, S., Sasaki, T. The transsylvian translimen insular approach to the crural, ambient and interpeduncular cisterns. *Acta Neurochir (Wien)*, 147: 863–869, 2005.
12. Wang, L., Zhang, MZ., Zhang, W., Zhao, SF., Zhao, JZ., Jia, JX. Clinical and pathological characteristics of septum pellucidum tumor and choice of surgical approaches for its resection. *Chin Med J*, 118 (15): 1244, 2005.
13. Ribas G.C., Yasuda A., Ribas E.C., Nishikuni N., Rodriguez A. Surgical anatomy of microneurosurgical sulcal key points. *Operative Neurosurgery* 4, Vol 59, Oct, 177 – 211, 2006.
14. Kaya, A.H., Dagainar, A., Topal, A., Senel, A., Iyigun, O. Stereotactically guided craniotomy for transsulcal exposure of small subcortical lesions adjacent to eloquent areas. *Neurosurgery Quarterly*, Vol 18, Iss 2, March 130-132, 2008.
15. Dagioglu, E., Ergungor, F., Polat, E., Nacar, O. Microsurgical resection of supratentorial cerebral cavernomas. *Turk Neurosurg.*, Jul., 20(3): 348-52, 2010.
16. Salcman, M. The Surgical Management of Gliomas. *The Practice of Neurosurgery*, Vol I, 649 – 670, 1996.
17. Mikuni N, Hashimoto N. A minimally invasive transsulcal approach to the paracentral inner lesion. *Minim Invasive Neurosurg.* Oct;49(5):291-5, 2006.
18. Yasargil MG. Microneurosurgery: volume 3B. Surgical concerns. New York 7 Thieme; p. 25- 53, 1988.
19. Oka, H., Kawashima, M., Shimizu, S., Utsuki, S., Osawa, S., Sato, K., Fujii, K., Rhoton Jr., A.L. Microsurgical anatomy of the lateral ventricle and surgical approaches. *Japanese Journal of Neurosurgery*, Volume 20, Issue 6, Pages 418-423, 2011.