



Original Contribution

EFFECT OF *CORNUS MAS* METHANOLIC EXTRACT ON MORPHOLOGICAL AND FUNCTIONAL CHANGES IN TESTES OF WISTAR RATS

B. Abdollahi¹, S. M. Banan Khojasteh^{2*}, M. Mesgari Abbasi¹, V. Nejati³

¹Drug Applied Research Center, Tabriz University of Medical Sciences, Tabriz, Iran

²Department of Animal Biology, Faculty of Natural Sciences, University of Tabriz, Tabriz, Iran

³Department of Biology, Faculty of Sciences, University of Urmia, Urmia, Iran

ABSTRACT

Fertility control with medicinal plants has been reported in ancient and modern medical literature. In this research, the effects of methanolic extract of *Cornus mas* on morphological and functional changes in testes were investigated in male wistar rats. Forty-eight rats divided into 6 groups and methanolic extract of *Cornus mas* was administered at four doses 400, 200, 100, and 50mg.kg⁻¹ for 21 days. Animals in control placebo group were received normal saline for the same duration. At the end of experimental period, animals were sacrificed and their blood and testes samples were collected for the analysis. Body and testes weights, reproductive hormonal profile, and testicular histoarchitecture were assessed. The results revealed that there was no significant alteration in serum FSH, LH, and testosterone concentration between control and treated groups. However, *Cornus mas* treatment caused significant changes in histological appearance of the testes. Since all the tubules were not influenced equally, it cannot be concluded that *Cornus mas* has an antifertility effect, therefore, further studies are warranted for more clarification.

Key words: *Cornus mas*, Testes, Testosterone, LH, FSH, Rat

INTRODUCTION

Population explosion is a major problem that is rising tremendously and this may drastically affect the economic growth and the control of population is a global and national public health concern. On the other hand, the options available to men for fertility control are much more limited compared to those of women (1).

Nearly 80% of the world populations rely on traditional medicines for primary health care, most of which involve the use of plant extracts (2). Some plant varieties have been used for the treatment of ulcer, hypertension, diabetes, and some male reproductive organs or to induce infertility without proper knowledge of their functions (3, 4).

***Correspondence to:** S. M. Banan Khojasteh,
Department of Animal Biology, Faculty of Natural
Sciences, University of Tabriz, e-mail:
smbanan@tabrizu.ac.ir

Current methods of contraception have side effects and result in an unacceptable rate of unwanted pregnancies (5). Thus, there is a need to replace these methods by safe and effective ones such as the plant based contraceptives.

Worldwide consumption of herbal therapy has markedly increased. Cornelian cherry (*Cornus mas* L.) is an example that is used in traditional therapy and as a food preservative. *Cornus mas* L. (*cornaceae* family) known as the European and Asiatic cornelian cherry is a species of dogwood native to southern Europe and south-west Asia (6).

Cherry fruits are a good source of antioxidant and they contain phenol, ascorbic acid, as well as anthocyanin (6). Furthermore fruits are rich in polysaccharides, organic acid and tannin (7, 8).

Fruits from several *Cornus spp.* have been used to improve liver and kidney functions and they

are known for their analgesic, diuretic and anti-diabetic properties (9). They have also been used for the medical treatment of gastrointestinal disorder and diarrhea and they have anti-bacterial, anti-allergic, and antimicrobial activities (10).

Despite the wide usage of this fruit, there have been very limited studies related to the effects of cornelian cherry especially on the male reproductive system. In the present study, we have studied the effects of *Cornus mas* L. methanolic extract on male reproductive functions and organs.

MATERIALS AND METHODS

Animals: In the present study forty-eight sexually mature and clinically healthy male Wistar rats weighing between 200-300 g were used. The rats were kept at a room temperature of $22\pm 3^{\circ}\text{C}$ and 12h light-dark cycle, in the animal house of the Medical University of Tabriz. Rats were fed on standard laboratory chew and water *ad libitum*.

Plant extract: Approximately 2.5 kg *Cornus mas* mature fruits were purchased from a local market from East Azerbaijan province (Arasbaran region) in August 2012. The fruits were washed and their seeds were removed, then they were open air dried for two weeks. The powdered fruits were extracted with MeOH (8L, 72h) at room temperature to obtain a crude extract (590 g) after evaporation under vacuum. The final residue was dissolved in 45 % hydroalcoholic solution.

Grouping: Animals were randomly allocated to six groups (Groups I-VI). Each group (eight animals per group) was housed in separate polypropylene cages, and treated as follows: Group I: untreated controls, group II: served as placebo and received normal saline, groups III-VI: treated daily with *Cornus mas* methanolic extract at doses of 400, 200, 100, 50 mg/kg of body weight respectively for 21 days, intraperitoneally.

Sample preparation: After the last treatment, blood samples (2ml) were taken from each animal by cardiac puncture. The samples were immediately transferred into heparinized tubes.

The plasma was removed and stored at -20°C until assaying. After the blood collection, the animals were weighed and decapitated.

Hormonal assay: One-milliliter blood samples were obtained and the sera were separated by centrifugation and stored at -20°C for the subsequent hormone assays. Serum testosterone, luteinizing hormone (LH), and follicle stimulating hormone (FSH) levels were measured by ELISA kits.

Histological study of the testis: The testes of all rats were dissected out, weighed, and then immediately fixed in formaldehyde solution (10%). The testes were remained in formalin 10% for 48h. They were washed with tap water during 2h and passed into different amounts of alcohol. The testes, then, were cut at the thickness of 5 μm and stained with Mayer's haematoxylin and eosin. The observations were made with 250 \times and 400 \times magnifications (ocular, 10 \times) with the Olympus BX51 light microscope.

Statistical analysis: The data were expressed as mean \pm ESM differences between control and treatment groups and statistical evaluation of data was performed using one-way analysis of variance (ANOVA) and Duncan multiple range test as a post hoc test. Means found to be significantly different when $P < 0.05$.

All stages of the study were performed according to the requirements of the Ethical Committee of the University of Tabriz.

RESULTS

Body and organ weights: As shown in **table 1**, non-significant differences were found between initial and final body weights of *Cornus mas*-treated rats and control ones (**Table 1**). *Cornus mas* treatment also had no effect on the weight of the testes in all treated rats compared to controls ($P > 0.05$).

Effects of *Cornus mas* extract on serum hormones concentration: The present study revealed no significant alterations in blood testosterone, LH, and FSH concentrations of treatment groups as compared with those of controls (**Table 1**).

Table 1. Effects of *Cornus mas* administration on body and testes weights, and serum levels of testosterone, FSH and LH in male rats.

Groups	Body weight(g)	Testosterone (ng/ml)	LH (mIU/ml)	FSH(mIU/ml)	Testes weight (g)	P level
Control	181±19.5	0.69±0.22	1.14±0.85	0.65±0.14	2.45±0.67	P>0.05
Control placebo	179±18.48	0.75±0.46	1.10±0.76	0.59±0.12	2.47±0.46	P>0.05
<i>C. mas</i> 400mg.kg ⁻¹	175±14.22	1.17±0.87	2.12±0.87	0.89±0.09	2.55±0.64	P>0.05
<i>C. mas</i> 200mg.kg ⁻¹	180±12.98	0.99±0.24	2.05±0.79	0.83±0.14	2.44±0.72	P>0.05
<i>C. mas</i> 100mg.kg ⁻¹	172±13.21	0.93±0.59	1.19±0.65	0.75±0.15	2.42±0.51	P>0.05
<i>C. mas</i> 50mg.kg ⁻¹	178±16.4	0.78±0.48	1.13±0.91	0.78±0.12	2.41±0.70	P>0.05

* Data has been reported as Mean±SD in all groups

Histopathology findings: Testes of untreated controls and with vehicle treated controls showed normal histological features in nearly all the seminiferous tubules. By contrast, marked alterations were observed in the histoarchitecture of the testis in high *Cornus mas*-treated (400, 200, 100 mg.kg⁻¹.b.w) rats (**Figures 3 to 5**). Non- uniform degenerative changes such as dissociation of germinal epithelium, reduction of

luminal epithelial thickness and severe lytic necrosis of seminiferous tubules as well as vacuolation were observed in the testes of rats treated with 400, 200, and 100 mg.kg⁻¹/b.w of *Cornus mas* for 21 days. Spermatid arrest, decreased numbers of seminiferous epithelial cells and numerous intratubular multinucleated spermatids were also seen in some tubules.

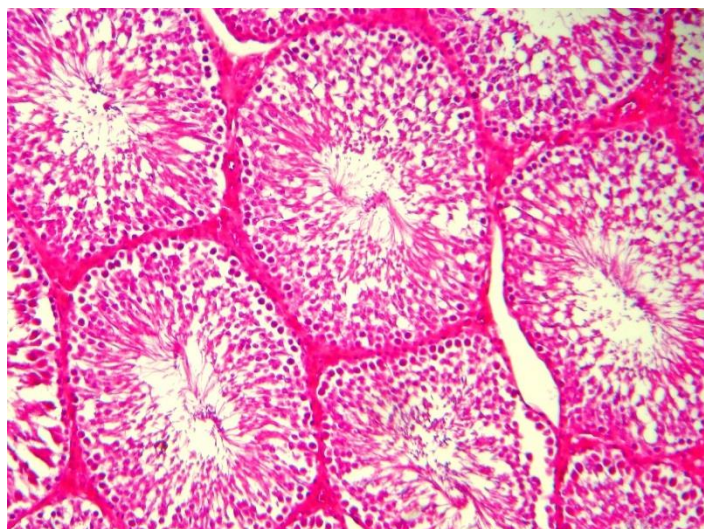


Figure 1. Testis of rat belonged to placebo group. Histological structure shows normal structure (magnification: X250).

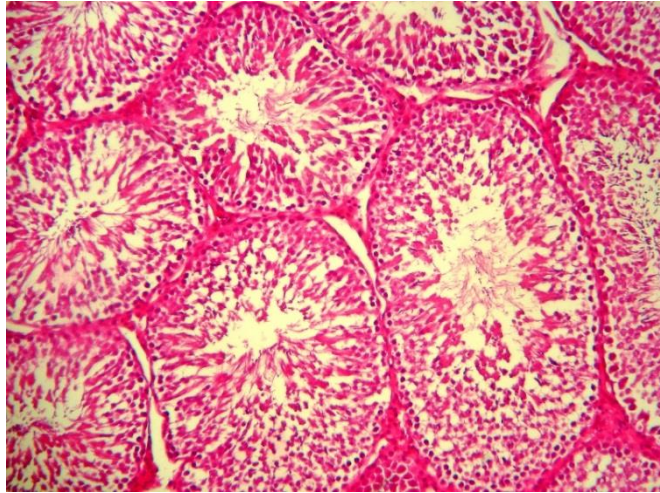


Figure 2. Microscopic appearance from testis tissue of a rat belonged to group II, showing normal appearance (magnification: X250).

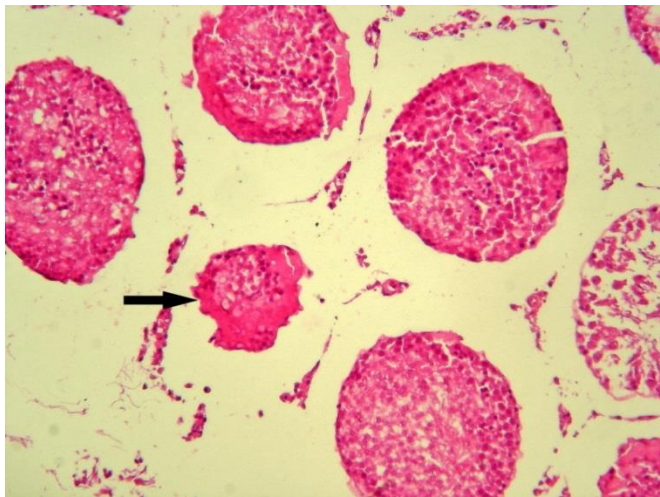


Figure 3. Testis of rat treated with 400 mg.kg^{-1} of *C. mas* extracts (magnification: X250). Degenerative changes and severe lytic necrosis of seminiferous tubules (arrow) is prominent.

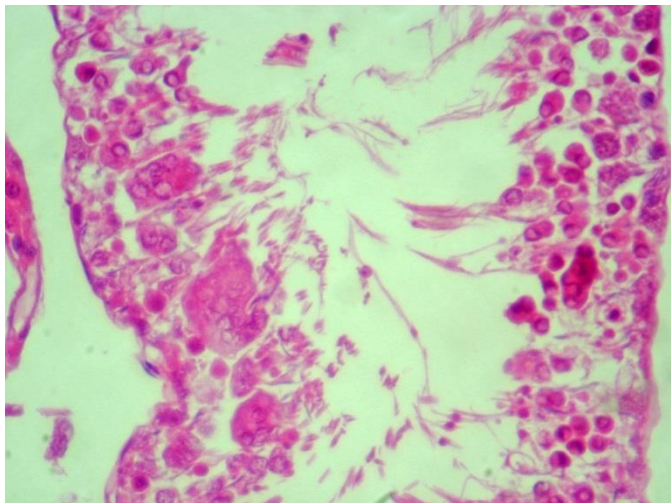


Figure 4. Testis of rat group treated with $200 \text{ mg.k}^{-1}\text{g}$ of *C. mas* extracts, showing arrested spermatogenesis and intratubular multinucleated giant cells (magnification: X400).

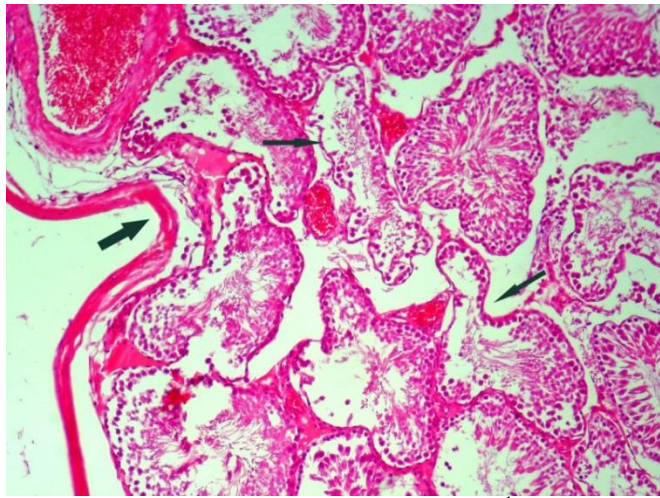


Figure 5. Testis of rat treated with 100 mg.kg⁻¹ of *C. mas* extracts. Shrinkage of testis is characterized by invagination (thick arrow) of tunica albuginea. Hyperemia is severe and degenerated tubules are collapsed (thin arrows) (magnification: X250).

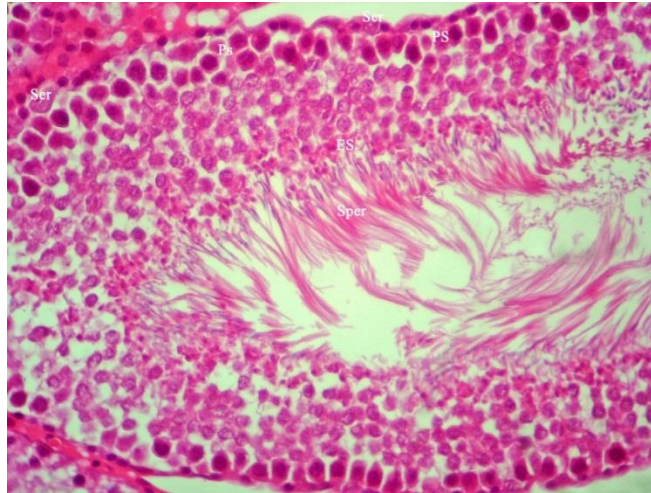


Figure 6. Testis of rat treated with 50 mg.kg⁻¹ of *C. mas* extracts. Histological appearance of testis is near to normal. Notice the normal Sertoli cells (ser), preleptotene spermatocytes (PS), elongated spermatides (ES) (magnification: X400).

DISCUSSION

The present results indicate that the administration of different doses of *Cornus mas* for 21 days had no significant effect on weight of testis and body. In the present study, serum hormonal level of testosterone, LH, and FSH remained unchanged, but the treatment caused non-uniform degenerative changes in the seminiferous tubules.

Our results showed non-significant changes in body weight of *Cornus mas* treated rats after 21 days of treatment. Similar results have been

reported with the extract of *Leptadenia hastata* in rats (11). The results indicated that the treatment did not cause alterations in the weights of testes. Unchanged testis weight was also revealed in oral administration of *Piper nigrum* for 20 days (12).

Testosterone, luteinizing hormone (LH), and follicle stimulating hormone (FSH) are important factors in the diagnosis of infertility in male (13) which they were unchanged in the present study. FSH is essential for initiating spermatogenesis and maturation of spermatozoa. High

concentration of FSH may lead to germinal cells injury and it is associated with azospermia and oligospermia. On the other hand, LH directly stimulates the spermatogenesis via testosterone, and testosterone level regulates LH concentration (14).

The present results showed that serum testosterone level was not significantly changed and it confirmed that in spite of the degeneration of germinal epithelium, the Leydig cells are unaffected. This is similar to that observed in rats receiving different doses of Valproate twice daily for 90 days (15).

Serum level of LH was not altered in *Cornus mas* treated animals. According to Lafuente *et al.*, (2008) oral administration of cadmium has no effect on serum level of LH in both pubertal and postpubertal rats (16). In our study the concentration of FSH remained unchanged between control and treatment groups, as LH. It has also been reported that in green tea treated rats, FSH level did not modified significantly (17). The effects of Genistein (18) and Methoxychlor (19) on serum FSH were the same as in our study. Obianime *et al.*, (2010) proved that *Ocimum gratissimum* extract caused no significant effects on the serum levels of testosterone, LH, and FSH (20). Although the mentioned agents did not alter serum hormonal level, but they have changed the histoarchitecture of testis and shown antifertility effects.

Methanolic extract of *C. mas* altered histopathological features in testes receiving higher doses (400, 200 and 100 mg.kg⁻¹/b.w for 21 days). Since, *Cornus mas* had no significant effects on the reproductive hormonal profile but adversely affected testicular histology; it clearly indicates that the effects of *Cornus mas* may mainly be due to direct injurious effects on the seminiferous tubules, without significant effects on the hypothalamo-pituitary function.

According to this study, affected tubules showed disorganized germ epithelium, degenerated and necrotic cells and reduction of germ epithelium. Similar histological changes have also been reported in treatments with *Achillea millefolium* (2, 21), *Achillea santolina* (22), gossypol (23), and *Trypterigium wilfordii* (24). Other degenerative changes in our study including

intraepithelial vacuolation, formation of giant cells, and loosening of germinal epithelium were look alike to testes of P mice after treatment with *Azadirachta indica* (25), *Allamanda cathartica* (26), and other antispermatogenic factors like gossypol tetra-acetic acid (27), nitrofurazone (28) and SC 12937 (29).

Multinucleated giant cells were observed in the germ epithelium of our treated animals. This might be caused by cell cycle blockage or by a cell proliferation stimulus. These cells have also been noticed in mouse testis after efferent duct ligation (30), vasectomy (31), and treatment with aqueous leaf extract of *Azadirachta indica* (25). These cells have also been observed with the use of testosterone propionate and 5-thio-D-glucose (32, 33).

The exact mechanism of these effects is not clear and might be due to substances present in *Cornus mas* extract, which leads to its antispermatogenic effects. It should be noted that in the study of herbal extracts, we cannot attribute the observed biological effects to a particular constituent, because of the presence of many other compounds in the plant extracts (34).

It is likely that the pathological conditions in affected seminiferous tubules in the testes of *Cornus mas*-treated rats were dose-dependent. On the other hand, all the tubules were not influenced equally in this study. Therefore, it cannot be concluded that *Cornus mas* potentially has an antifertility effects. It has shown that the plant extracts exhibit different activities over a concentration range as agonist or antagonist, indicating an estrogen receptor-mediated effect at low concentration and an estrogen receptor independent effect at higher concentration (34).

In conclusion, our results suggest that the administration of *Cornus mas* extract may impose toxic effects on fertility in male rats. Further studies must be performed to identify and isolate its active component(s) that affects fertility in male rats and to determine its mechanism of action.

CONCLUSION

In conclusion, our findings suggest that the *Cornus mas* treatment in doses employed in rat causes significant alterations in the testicles. Since all the tubules were not influenced equally, it cannot be concluded that *Cornus mas* has an

antifertility effect, therefore, further studies are warranted for more clarification.

ACKNOWLEDGMENTS

Thanks are due to drug applied research center of Tabriz University of Medical Sciences, Iran.

REFERENCES

- Mishra, N., Joshi, S., Tandon, V. L., Munjal, A., Evaluation of anti-fertility potential of aqueous extract of *Bougainvillea spectabilis* leaves in swiss Albino mice. *International Journal of Pharmaceutical Science and Drug Research*, 9: 19-23, 2009.
- Parandin, R., Ghorbani, R., Effects of alcoholic extract of *Achillea mellifolium* flowers on fertility parameters of male rats. *International Journal of PharmTech*, 2: 2492-2496, 2010.
- Mbongue, F. G. Y., Kamtchouing, P., Essame, O. J. L., Yewash, P. M., Dimo, T., Lontsi, D., Effect of the aqueous extract of dry fruits of *Piper guineense* on the reproductive function of adult male rats. *Indian Journal of Pharmacology*, 37: 30-32, 2005.
- Priya, G., Saravanan, K., Renuka, C., Medicinal plants with potential antifertility activity- A review of sixteen years of herbal medicine research. *International Journal of PharmTech Research*, 4: 481-494, 2012.
- Gupta, R. S., Sharma, R., A review on medicinal plants exhibiting antifertility activity in males. *Natural Product Research*, 5: 389-410, 2006.
- Pawlowska, A. M., Camangi, F., Braca, A., Quali-quantitative analysis of flavonoids of *Cornus mas* L. (Cornaceae) fruits. *Food Chemistry*, 119:1257-1261, 2010.
- Demir, F., Kalyoncu, I. H., Some nutritional, pomological and physical properties of cornelian cherry (*Cornus mas* L.). *Journal of Food Engineering*, 60: 335-341, 2003.
- Yilmaz, K. U., Ercisli, S., Zengin, Y., Sengul, M., Kafkas, E. Y., Preliminary characterisation of cornelian cherry (*Cornus mas* L.) genotypes for their physico-chemical properties. *Food Chemistry*, 114: 408-412, 2009.
- Samec, D., Piljac-Zegarac, J., Postharvest stability of antioxidant compounds in hawthorn and cornelian cherries at room and refrigerator temperatures— Comparison with blackberries, white and red grapes. *Scientia Horticulturae*, 131: 15-21, 2011.
- Tural, S., Koca, I., Physico-chemical and antioxidant properties of cornelian cherry fruits (*Cornus mas* L.) grown in Turkey. *Scientia Horticulturae*, 116: 362-366, 2008.
- Bayala, B., Telefo, P. B., Bassole, I. H. N., Tamboura, H. H., Belemtougri, R. G., Sawadogo, L., Malpoux, B., Dacheux, J. L., Anti-spermatogenic activity of *Leptadenia hastata* (Pers.) decne leaf stems aqueous extracts in male wistar rats. *Journal of Pharmacology and Toxicology*, 6: 391-399, 2011.
- Mishra, R. K., Singh, S. K., Antispermato-genic and antifertility effects of fruits of *Piper nigrum* L. in mice. *Indian Journal of Experimental Biology*, 47: 706-714, 2009.
- Zabul, J., Mierzejewski, W., Rogoza, A., Usefulness of examininh gonadotropin hormones and testosterone in men with abnormal semen. *Ginekol-pol*, 65: 71-76, 1994.
- Bargmann, M., Behre, H., Nieschlag, E., Serum FSH and testicular morphology in male infertility. *Clinical Endocrinology*, 40: 133, 1994.
- Røste, L. S., Taubøll, E., Isojärvi, J. A. T., Pakarinen, A. J., Huhtaniemi, I. T., Knip, M., Gjeristad, L., Effects of chronic valproate treatment on reproductive endocrine hormones in female and male Wistar rats. *Reproductive Toxicology*, 16: 767-773, 2002.
- Lafuente, A., Márquez, N., Pérez-Lorenzo, M., Pazo, D., Esquifino, A. I., Pubertal and postpubertal cadmium exposure differentially affects the hypothalamic-pituitary-testicular axis function in the rat. *Food and Chemical Toxicology*, 38: 913-923, 2000.
- Chandra, A. K., Choudhury, S. R., De, N., Sarkar, M., Effect of green tea (*Camellia sinensis* L.) extract on morphological and functional changes in adult male gonads of

- Alino rats. *Indian Journal of Experimental Biology*, 49: 689-697, 2011.
18. S., Nakajima, Y., Inoue, K., Nakasawa, H., Nakajin, S., Genistein administration decreases serum corticosterone and testosterone levels in rats. *Life Science*, 74: 733-742, 2003.
 19. A., Cabaleiro, T., Caride, A., Esquifino, A. I., Toxic effects of methoxychlor administered subcutaneously on the hypothalamic-pituitary-testicular axis in adult rats. *Food Chemical Toxicology*, 46: 1570-1575, 2008.
 20. Obianime, A. W., Aprioku, J. S., Esomonu, C. T. O., Antifertility effects of aqueous crude extract of *Ocimum gratissimum* L. leaves in male mice. *Journal of Medicinal Plants Research*, 4: 809-816, 2010
 21. Montanari, T., De Carvalho, J. E., Dolder, H., Antispermatic effect of *Achillea millefolium* L. in mice. *Contraception*, 58: 309-313, 1998.
 22. Golalipour, M. J., Khori, V., Azarhoush, R., Nayebpour, M., Azadbakht, M., Effect of *Achillea santolina* on mice spermatogenesis. *Daru*, 12: 36-39, 2004.
 23. Haider, S. G., Passia, D., Chen, K. Q., Stumpf, W. E., Reversible changes in rat spermatogenesis induced by an antifertility substance (gossypol). A histochemical report. *Acta Histochemica*, 77: 185-91, 1985.
 24. Qian, S. Z., Zhong, C. Q., Xu, Y., Effect of *trypterygium wilfordii* on the fertility of rats. *Contraception*, 33: 105-10, 1986.
 25. Mishra, R. K., Singh, S. K., Effect of aqueous leaf extract of *Azadirachta indica* on the reproductive organs in male mice. *Indian Journal of Experimental Biology*, 43: 1093-1103, 2005
 26. Singh, A., Singh, S. K., Reversible antifertility effect of aqueous leaf extract of *Allamanda cathartica* L. in male laboratory mice. *Andrologia*, 40: 337-345, 2008.
 27. Singh, S. K., Rath, S. K., Histologic changes in the mouse testis after treatment with gossypol tetra-acetic acid. *Archives of Histology and Cytology*, 53: 393-396, 1990.
 28. Singh, S. K., Chakravarty, S., Effect of nitrofurazone on the reproductive organs in adult male mice. *Asian Journal of Andrology*, 3: 39-44, 2001.
 29. Singh, S. K., Chakravarty, S., Antispermatic and antifertility effects of 20,25-diazacholestrol dihydrochloride in mice. *Reproductive Toxicology*, 17: 37-44, 2003.
 30. Singh, S. K., Abe, K., Light and electron microscopic observations of giant cells in the mouse testis after efferent duct ligation. *Archives of Histologica Japponica*, 50: 579-585, 1987.
 31. Singh, S. K., Chakravarty, S., Histologic changes in the mouse testis after bilateral vasectomy. *Asian Journal of Andrology*, 2:115-120, 2000.
 32. Abdi, S. H., Wahidul, H., Effect of testosterone on the histological structure of the testis of adult albino rats. *Indian Journal of Medical Research*, 61:1207-1211, 1973.
 33. Majumdar, S. K., Udelsman, R., Fine structure of mouse testes following intraperitoneal treatment with 5-thio-D-glucose. *Journal of Heredity*, 70:194-8, 1979.
 34. Karbalay-Doust, S., Noorafshan, A., Dehghani, F., Panjehshahin, M. R., Monabati, A., Effects of Hydroalcoholic Extract of *Matricaria chamomilla* on Serum Testosterone and Estradiol Levels, Spermatozoon Quality, and Tail Length in Rat. *IJMS*, 35: 122-128, 2010.