Bulgarian Journal of Veterinary Medicine, 2020 ONLINE FIRST
ISSN 1311-1477; DOI: 10.15547/bjvm.2370

Original article

BIOMETRIC PARAMETERS AND COMPUTER ASSISTED ANALYSIS OF PIXEL DISTRIBUTION ON B-MODE TESTICULAR ULTRASONOGRAM IN YOUNG AND SEXUALLY MATURE RAMS

S. YOTOV

Department of Obstetrics, Reproduction and Reproductive Disorders, Faculty of Veterinary Medicine, Trakia University, Stara Zagora, Bulgaria

Summary

Yotov, S., 2020. Biometric parameters and computer assisted analysis of pixel distribution on B-mode testicular ultrasonogram in young and sexually mature rams. *Bulg. J. Vet. Med.* (online first).

This study was designed to investigate the relationships between basic biometric parameters and pixel distribution in predetermined regions of B-mode testicular ultrasonogram in young and sexually mature rams by computer assisted analysis. The animals were separated in two groups: group I (young rams, aged 5–8 months; n=6) and group II (sexually mature rams, aged 14–18 months; n=6). Biometric parameters as age, body weight and scrotal circumference were determined by routine methods. A trans-scrotal ultrasonography of both testes was performed with 7 MHz linear transrectal probe by the same operator with focus, gain and brightness values kept constant during the study. The ultrasound images were obtained in a longitudinal view plane and frozen when visualisation of the testicular mediastinum was clear and apparent. All images were transferred to a computer, converted to gray-scale (0–255 pixels) and submitted to pixel distribution analysis using Image ProPlus 7.0 analytical software and option range statistics. The pixel distribution analysis in the same region for left and right testes was based on the pixel ranges classification for different biological tissues (blood, lipids, muscle, fibrous and calcium) and expressed as colour area in percentages. The arithmetic mean of values for the left and right testis was accepted as a final value for each ram. The data for both groups were statistically processed, compared and the relationships between the biometric parameters and different pixel ranges were determined. Significant differences ($P<0.05$) among the groups were recorded for all biometric parameters and the lipid area only. The biometric parameters correlated positively ($R\geq0.92$; $P<0.05$) each with the other, while their relationship ($R\leq -0.94$; $P<0.05$) with the lipid area and the correlation between muscle and fibrous area were negative ($R= -0.92$; $P<0.05$). In conclusion, the pixel distribution analysis of a predetermined region of B-mode testicular ultrasonogram based on pixel ranges classification for different biological tissues can be used for detection of testicular parenchyma changes in rams. Future comparative histologic and ultrasound investigations are needed to determine correct pixel values for different biological tissues in the testes of young and sexually mature rams.

Key words: biometry, pixel distribution analysis, ram, testes

INTRODUCTION

Computer-assisted analysis of ultrasound images of reproductive organs in ruminants can improve their interpretation and increase the diagnostic value of the ultrasound method (Pierson & Adams, 1995; Giffin *et al.,* 2009; Ahmadi *et al.,* 2012; Elbaz & Razek, 2018). Recently, the relationship between echogenicity of testicular parenchyma and semen characteristics in male animals are intensively studied (Tomlinson *et al.,* 2017; Saaed & Zaid, 2018; Camela *et al.,* 2019; Hedia *et al.,* 2020). Different authors report significant correlations between some biometric indicators, ultrasound testicular parameters and semen quality in rams and use this information for determination of testicular maturation (Chandolia *et al.,* 1997; Giffin *et al.,* 2014; da Silva Ribeiro *et al.,* 2017; Yotov & Fasulkov, 2020).

The numerical pixel values and pixel standard deviation are outlined as criteria of testicular echogenicity and pixel heterogeneity and depend on histomorphological characteristics of the testicular tissues and age of the rams (Ahmadi *et al.,* 2013; Saaed & Zaid, 2018; Camela *et al.,* 2019). In human medicine, a quantitative pixel distribution analysis is used for pixel-level tissue classification in B-mode ultrasonogram (Pazinato *et al.,* 2014). On this base five types of tissues: blood, lipids, muscle, fibrous, and calcium were presented. An information for assessment of testicular echotexture in rams based on the pixel ranges classification for different biological tissues is not available.

This study was designed to investigate the relationships between basic biometric parameters and pixel distribution in predetermined region of B-mode testicular ultrasonogram in young and sexually mature rams by computer assisted analysis.

MATERIALS AND METHODS

The investigation was carried out with twelve clinically healthy rams (Pleven Blackhead breed) without previous semen collection, allocated in two groups: group I (young rams, aged 5–8 months, body weight 34±6.3 kg; n=6) and group II (sexually mature rams, aged 14–18 months, 62±6.4 kg; n=6). All animals were housed in free barns, located at N 42.25 and E 25.38. Daily ration included concentrate, hay, straw, mineral and vitamin supplements and water *at libitum*. The experiment was performed in the breeding season (July). The study was conducted in accordance with the recommendations of Animal Ethics Committee and local regulations for human attitude and animals protection.

The biometric parameters age, body weight (BW) and scrotal circumference (SC) were determined by the routine methods. A trans-scrotal ultrasonography of both testes was performed with ultrasound scanner SonoScape S2 Vet (SonoScape Co. LTD, Shenzhen, China) and 7 MHz linear transrectal probe by the same operator, and the values for focus, gain and brightness were kept constant during the study. The ultrasound images were obtained in a longitudinal view plane and frozen when visualisation of the testicular mediastinum was clear and apparent. All images were transferred to a computer, followed by convertion to gray-scale (0–255 pixels) and submission to pixel distribution analysis (Image ProPlus 7.0 analytical software, Media Cybernetics Inc., San Diego, CA, USA) and option range statistics. The pixel distribution in the same region for left and right testes was based on the pixel ranges classification for different biological tissues: blood

(0–16 pxs; red), lipids (17–37 pxs; yellow), muscle (38–83 pxs; blue), fibrous (84–160 pxs; green) and calcium (161–255 pxs; orange) and expressed as colour area in percentages (Pazinato *et al.,* 2014). The arithmetic mean of values for left and right testis was accepted as a final value for each ram.

The data for both groups were statistically processed by Statistica version 7.0 software (Stat-Soft., 1984-2000 Inc., Tulsa, OK, USA). The parameters for each group were presented as mean ± standard deviation. The values between both groups were compared by *t*-test for comparison of two means. The relationships between the basic parameters and different pixel ranges were determined by Pearson product moment analysis and Person's coefficient of correlation (R) was recorded. Statistical significance was considered at P level <0.05.

RESULTS

The mean values of age, body weight and scrotal circumference differed significantly (P<0.01) between both groups of rams (Table 1).

The biometric parameters age, BW and SC correlated positively (R≥0.92; P<0.05) each with the other, while their relationships (R≤ −0.94; P<0.05) with the lipid area were negative (Table 2). Despite the presence of clear visual distinction between coloured ranges for investigated biological tissues on both ultrasonograms (Fig. 1), statistical differences between their mean values were not recorded. Only the correlation between muscle and fibrous areas was negative (R= −0.92; P<0.05).

DISCUSSION

The assessment of rams' reproductive ability before their introduction in the breeding process is a key factor for effective reproduction. The selection of males when they achieve puberty allows exclusion of rams with low fertility from the flock (Ridler *et al.,* 2012). Ultrasound examination for early detection of ram reproductive capacity is a very important

Table 1. Biometric parameters and areas of pixel distribution in B-mode testicular ultrasonograms of different groups of rams (mean ± SD)

	Group I (n=6) young rams	Group II (n=6) sexually mature rams	P values
Biometric parameters			
Age (months)	6.5±1.60	16.0±2.2	0.01
Body weight (kg)	35.0±8.30	70.0±7.1	0.01
Scrotal circumference (cm)	18.8±5.90	32.0±4.0	0.01
Area of pixel distribution (%)			
Blood (0–16 pxs)	0.23±0.10	0.12±0.40	0.56
Lipids (17–37 pxs)	16.57±13.10	2.25±2.01	0.04
Muscle (38–83 pxs)	41.51±30.05	23.32±5.08	0.17
Fibrous (84–160 pxs)	41.78±42.89	73.28±6.63	0.06
Calcium (161–250 pxs)	0	1.07±0.42	–

pxs = pixels.

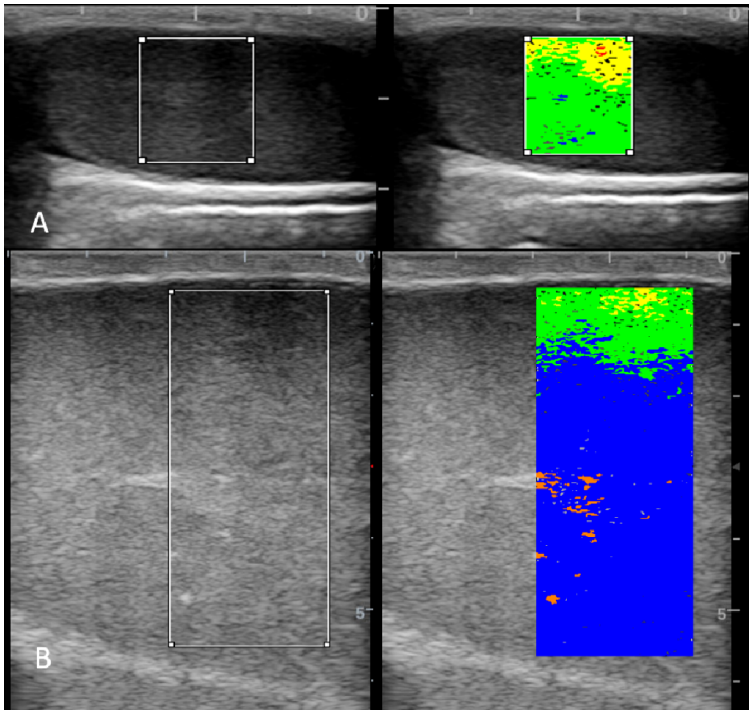

Fig. 1. B-mode testicular ultrasonogram and colour pixel distribution analysis of testicular ultrasonogram in young (**A**) and sexually mature rams (**B**).

part from the complete reproductive assessment (Gouletsou & Fthenakis, 2010; Saaed & Zaid, 2018). The current study is the first report for pixel distribution analysis in a predetermined region of B-mode testicular ultrasonogram in young and sexually mature Pleven blackhead rams based on the coloured pixel ranges classification for different biological tissues.

The differences in the body weight and the scrotal circumference among the groups provided evidence for a significant effect of age on these biological parameters. The obtained values for scrotal circumference (18.8±5.9 cm and 32±4.0 cm) were close to those recorded in young and mature rams from Bulgarian Dairy Synthetic Population (Metodiev *et al.,* 2014) and Pleven Blackhead breeds (Yotov & Fasulkov, 2020). The positive correlations between abovementioned parameters and both significantly larger body weight and scrotal circumference in the older rams can be explained with advanced age and higher body weight of the animals. This is in agreement with previous reports (Koyuncu *et al.,* 2005; Allaoui *et al.,* 2014) for strong positive relationship of scrotal circumference with age and body weight of the rams. The negative relationships with the lipid area was an indicator for additional tissue changes.

B-mode, gray-scale ultrasonography provides detection of different alterations in the testicular echotexture. The ultrasonographic image is composed of pixels, directly connected with the tissues characteristics (Pirsonn & Adams, 1995; Chan-

dolia *et al.,* 1997). The visual difference between the coloured images of investigated biological tissues on both ultrasonograms did not correspond with statistically significant differences between their mean values. In this aspect, Urt *et al.* (2018) showed that the computer-assisted image analysis allowed for measurement of the tissues echotexture in a very objective way, imperceptible to the human eye. Ahmadi *et al.* (2013) determined a negative correlation between average pixel values of the testicular ultrasonogram and parenchymal protein content and a direct correlation of pixel heterogeneity with extractable lipids. Andrade *et al.* (2014) stated a proportional increase of the echogenicity with the age of the animals. According to Giffin *et al.* (2014) the testicular echogenicity was highly variable for rams at a different age of. Initially it was increased followed by a reduction, associated with the mitotic and postmitotic phases of spermatogenesis in prepubescent ram lambs. Camela *et al.* (2019) accepted the differences in testicular echotexture as a result of changes in testes' histomorphology around puberty. They explained the altered echotexture with seminiferous tubule area differentiation that occurred in the presence of more mature germ cells in the majority of seminiferous tubules. The registration of pixel values for calcified areas in older rams only can be indicator of previous pathology. Similar small lesions with calcification without manifestation of clinical and functional reproductive problems were observed in older males by Tomlinson *et al.* (2017).

All of the abovementioned indicates significant alterations in the percentage distribution of different biological tissues in testicular parenchyma during animal growth, which is associated with the pixel distribution in the ultrasound image. It also supports the application of the ultrasound method and computer assisted pixel distribution analysis of B-mode testicular ultrasonogram for *in vivo* detection of distinctive testicular characteristics. Nevertheless, future research with a large number of animals focused on standardisation of the pixel ranges according to the specificity of the testicular tissues in rams is necessary. Pazinato *et al.* (2014) also recommended defining the ranges of pixel values for the classification of each tissue. The correlation between the ultrasound virtual and real histology will confirm the quality of the proposed approach and accuracy of the method. The knowledge for values of testicular echogenicity throughout the year can provide useful references for predicting the testicular function in rams (Hedia *et al.,* 2020).

CONCLUSION

The pixel distribution analysis of a predetermined region in B-mode testicular ultrasonogram based on the pixel ranges classification for different biological tissues can be used for detection of testicular parenchyma changes in rams. Future comparative histologic and ultrasound investigations are needed to determine correct pixel values for the different biological tissues in the testes of young and sexually mature rams.

REFERENCES

Allaoui, A., B. Safsaf, W. Laghrour & M. Tlidjane, 2014. Factors affecting scrotal measurements and weight of ouled Djellal rams in Eastern and South-eastern Algeria. *APCBEE Procedia*, **8**, 260–265.

Ahmadi, B., C. Lau, J. L. Giffin, N. Santos, A. Hahnel, J. Raeside, C. Heather & P. M.

Bartlewski, 2012. Suitability of epididymal and testicular ultrasonography and computerized image analysis for assessment of current and future semen quality in the ram. *Experimental Biology and Medicine*, **237**, 186–193.

Ahmadi, B., A. Mirshahi, J. Giffin, M. E. F. Oliveira, L. Gao, A. Hahnel & P. M. Bartlewski, 2013. Preliminary assessment of the quantitative relationships between testicular tissue composition and ultrasonographic image attributes in the ram. *The Veterinary Journal*, **198**, 282–285.

Andrade, A. K. G., A. T. Soares, F. F. Freitas, S. V. Silva, C. E. Peña-Alfaro, A. M. Batista & M. M. P. Guerra, 2014. Testicular and epididymal ultrasonography in Santa Inês lambs raised in *Brazilian Animal Reproduction*, **11**, 110–118.

Camela, E. S. C., R. P. Nociti, V. J. C. Santos, B. I. Macente, M. Murawski, W. R. R.Vicente, P. M. Bartlewski & M. E. F. Oliveira, 2019. Changes in testicular size, echotexture, and arterial blood flow associated with the attainment of puberty in Dorper rams raised in a subtropical climate. *Reproduction in Domestic Animals*, **54**, 131–137.

Chandolia, R. K., P. M. Bartlewski, B. C. Omeke, A. P. Beard, N. C. Rawlings & R. A. Pierson, 1997. Ultrasonography of the developing reproductive tract in ram lambs: Effects of a GnRH agonist. *Theriogenology*, **48**, 99–117.

Elbaz, H.T. & E. M. A. Razek, 2019. Ultrasonographic monitoring of reproductive organs of Barki rams during early non-breeding season. *Journal of Advanced Veterinary Research*, **9**, 56–63.

da Silva Ribeiro, M.S., C. R. Quirino, A. B. Junior & A. Pacheco, 2017. Biometry and ultrasound evaluation of testicles and accessory glands in Santa Ines rams. *Revista Brasileira de Zootecnia*, **46**, 317–323.

Giffin, J. L., P. M. Bartlewski & Hahnel, A. 2014. Correlations among ultrasonographic and microscopic characteristics of prepubescent ram lamb testes. *Experimental Biology and Medicine*, **239**, 1606–1618.

Giffin, J. L., S. E. Franks, J. R. Rodriguez-Sosa, A. Hahnel & P. M. Bartlewski 2009. A study of morphological and haemodynamic determinants of testicular echotexture characteristics in the ram. *Experimental Biology and Medicine*, **234**, 794–801.

Gouletsou, P. G. & G. C. Fthenakis, 2010. Clinical evaluation of reproductive ability of rams. *Small Ruminant Research,* **92**, 45–51.

Hedia, M. G., M. S. El-Belely, S. T. Ismail, & A. M. Abo El-Maaty, 2020. Seasonal changes in testicular ultrasonogram pixel-intensity and their association with semen characteristics in rams. *Asian Pacific Journal of Reproduction*, **9**, 49–54.

Koyuncu, M., S. Kara Uzun, S. Ozis & S. Duru, 2005. Development of testicular dimensions and size, and their relationship to age and body weight in growing Kivircik (Western Thrace) ram lambs. *Czech Journal of Animal Sciences*, **50**, 243–248.

Metodiev, N., T. Ivanova & E. Raicheva, 2014. Onset of puberty of ram lambs. *Bulgarian Journal of Animal Husbandry*, **L I. (1–2)**, 17–21.

Pazinato, D. V., B. V. Stein, W. R. de Almeida, R. de O. Werneck, P. R. Mendes Júnior, O. A. Penatti, S. Torres Rda, F. H. Menezes & A. Rocha, 2016. Pixel-level tissue classification for ultrasound images. *IEEE Journal of Biomedical Health Information*, **20**, 256–267.

Pierson, R. A. & G. P. Adams, 1995. Computer-assisted image analysis, diagnostic ultrasonography and ovulation induction: Strange Bedfellows. *Theriogenology*, **43**, 105–112.

Ridler, A. L., S. L. Smith & D. M. West, 2012. Ram and buck management. *Animal Reproduction Science*, **130**, 180–183.

Saaed, F. F. & N. W. Zaid, 2018. Predictor ultrasonographic evaluation of the testis during pubertal age in ram lambs. *Ad-*

vances in Animal and Veterinary Sciences, **6**, 521–525.

Tomlinson, M., A. Jennings, A. Macrae & I. Truyers, 2017. The value of trans-scrotal ultrasonography at bull breeding soundness evaluation (BBSE): The relationship between testicular parenchymal pixel intensity and semen quality. *Theriogenology*, **89**, 169–177.

Urt, M. A. G., E. W. B. Bakarji, F. J. C. Faria, E. F. Santos & D. S. Costa, 2018. Lack of relationship between testicular echotexture and seminal characteristics in adult Texel rams. *Agricultural Sciences*, **9**, 936–946.

Yotov, S. A. & I. R. Fasulkov, 2020. Biometric indicators, testicular parameters and semen characteristics in peripubertal and postpubertal Pleven blackhead rams. *Advances in Animal and Veterinary Sciences*, **8**, 217–222.

Paper received 10.08.2020; accepted for publication 08.10.2020

Correspondence:

Stanimir Angelov Yotov,
Department of Obstetrics, Reproduction and Reproductive Disorders,
Faculty of Veterinary Medicine,
Trakia University,
6000 Stara Zagora, Bulgaria.
Tel: (+359) 42 699 513
e-mail: stanrad@abv.bg