Bulgarian Journal of Veterinary Medicine (2013), **16**, No 3, 145–158

AGE-RELATED MORPHOLOGY OF THE OSTRICH OVIDUCT (ISTHMUS, UTERUS AND VAGINA)

A. SHARAF, W. EID & A. A. ABUEL-ATTA

Department of Histology and Cytology, Faculty of Veterinary Medicine,
Zagazig University, Zagazig, Egypt

Summary

Sharaf, A., W. Eid & A. A. Abuel-Atta, 2013. Age-related morphology of the ostrich oviduct (isthmus, uterus and vagina). *Bulg. J. Vet. Med.*, **16**, No 3, 145–158.

Ostrich fertility is a very important measure of their reproductive efficiency, hence our interest in studying the ostrich oviduct. In our study, we found in fully mature birds a thin walled region between magnum and isthmus free of glands and considered as an area of transition called zona translucent. Also, the uterus was formed from a cranial short tubal part followed by a caudal large sac-like pouch. The mucosal folds of uterus are called uterine lamellae. The free borders of these lamellae were smooth, while their both sides were wrinkled. Most of these lamellae were directed longitudinally and converged towards the vagina. In pre-laying birds (3–3.5 years of age) a well developed membrane was found between the vagina and the urodeum. Afterwards in the laying hens we could not found this membrane. Histologically, the glandular buds were found to appear in lamina propria of the isthmus and uterus but not in the vagina of immature ostrich chicks and to become tubular branched glands in pre-laying hens and active, more branched, filled with secretory materials in laying ostrich hens. The cores of the mucosal folds in isthmus and uterus were filled with glands and free of glands in the vagina. Histochemically, in laying ostrich hens the isthmian and vaginal epithelium were reacted positively to PAS staining, while some individual PAS-positive secretory granules were present within the cytoplasm of the apical part of the uterine epithelium.

Key words: histochemistry, histology, gross anatomy, ostrich, oviduct

INTRODUCTION

The ostrich oviduct consisted from five regions; infundibulum, magnum, isthmus, uterus, and vagina (Sharaf *et al.*, 2012) and is suspended from the roof of the body cavity by a dorsal ligament, and continues ventrally as a ventral ligament and ends caudally as a muscular cord. There is a difference between the fertility of ostrich eggs in different farms (Badley, 1997; Bunter & Graser, 2000) despite a reproductive strategy that should guarantee high fertility through high rates of sperm supply and the presence of sperm storage tubules in the female (Bezuidenhout *et al.*, 1995; Holm *et al.*, 2000; Malecki & Martin, 2003). After a single copulation, ostriches would have a fertile period during which they could lay several fertilized eggs (Lake, 1975; Birkhead, 1988; Malecki & Martin, 2002). Therefore, high rates of egg fertilization should be a feature of ostrich reproduction. Despite advances in every area of production, fertility is still unsatisfactory (Deeming, 1999). In the commercial farms the fertility rate of ostrich eggs ranged from 40 to 90% (Deeming, 1996). When infertility is detected it is usually associated with the lack of sperm transfer due to either

inadequate mating or poor sperm production (Malecki & Martin, 2003). While those problems could be also caused by a male that deposits low numbers of sperm or none at all (Birkhead *et al.*, 1987), in addition the female may retain few sperm following copulation or retain sperm for fertilisation for only a short period (Bakst *et al.*, 1994). After ova released from the ovary, the ovulated ovum is gathered into the ostium by the action of the fimbriated region of the infundibulum. If spermatozoa are present, the ovum may be fertilised. The ovum traverses the oviduct and the albumen forms in the magnum, the shell membranes in the isthmus, the hard shell in the uterus, and the cuticle in the vagina. Also the vagina serves as a duct between the uterus and cloaca. The rationale of this study was to describe the morphological features of isthmus, uterus and vagina of the ostrich oviduct during different developmental stages with conventional histological and histochemical techniques.

MATERIALS AND METHODS

Animals

Four groups of female ostriches (*Struthio camelus*) were used for this study and the determination of age was based upon the records of ostrich farms. Each age group included six birds: immature ostriches (8–10 months; 15 months); pre-laying birds (36–42 months) and laying ostrich hens (60–72 months of age). After slaughter or accidental death of the birds, they eviscerated and the left oviduct were collected and directly immersed in PFA 10%.

Histological investigations

The isthmus, uterus and vagina from the left oviduct of each bird were taken just after sacrifice and evisceration, then immediately fixed in 10% neutral buffered formalin and routinely processed and embedded in paraffin. Paraffin sections (5–7 µm) were stained with Harris haematoxylin and eosin for general histological studies (Harris, 1900). The other used staining techniques were Crossmon's trichrome for demonstration of collagen fibres and smooth muscles (Crossmon, 1937), Periodic acid Schiff (PAS) for visualization of neutral mucopolysaccharides (McManus, 1946), alcian blue (pH 2.5) for visualization of acidic mucopolysaccharides (Steedman, 1950), Silver impregnation technique for visualization of reticular fibres (Gomori, 1937).

Morphometrical investigations

At least three samples from isthmus, uterus, and vagina of different ostriches were prepared from each age. The height of the epithelium, thickness of lamina propria, and thickness of regions wall were measured in comparison to infundibulum and magnum at different ages by means of a light microscope and an eye piece micrometer disc (ocular micrometer).

RESULTS

Gross anatomy

The ostrich oviduct was formed of five regions, infundibulum, magnum, isthmus, uterus, and vagina. Externally, a slight constriction was located between magnum and isthmus, appearing as a transitional thin-walled zone and considered as an area of transition, called zona translucent (Fig. 1A). The isthmus was short and less flexuous tube measuring 14 to 17 cm in length and 4.0 to 7.0 cm in width in the laying hens. However in prelaying ostrich hens the isthmus measured 7.0 to 9.0 cm in length and 1.5 to 2.5 cm

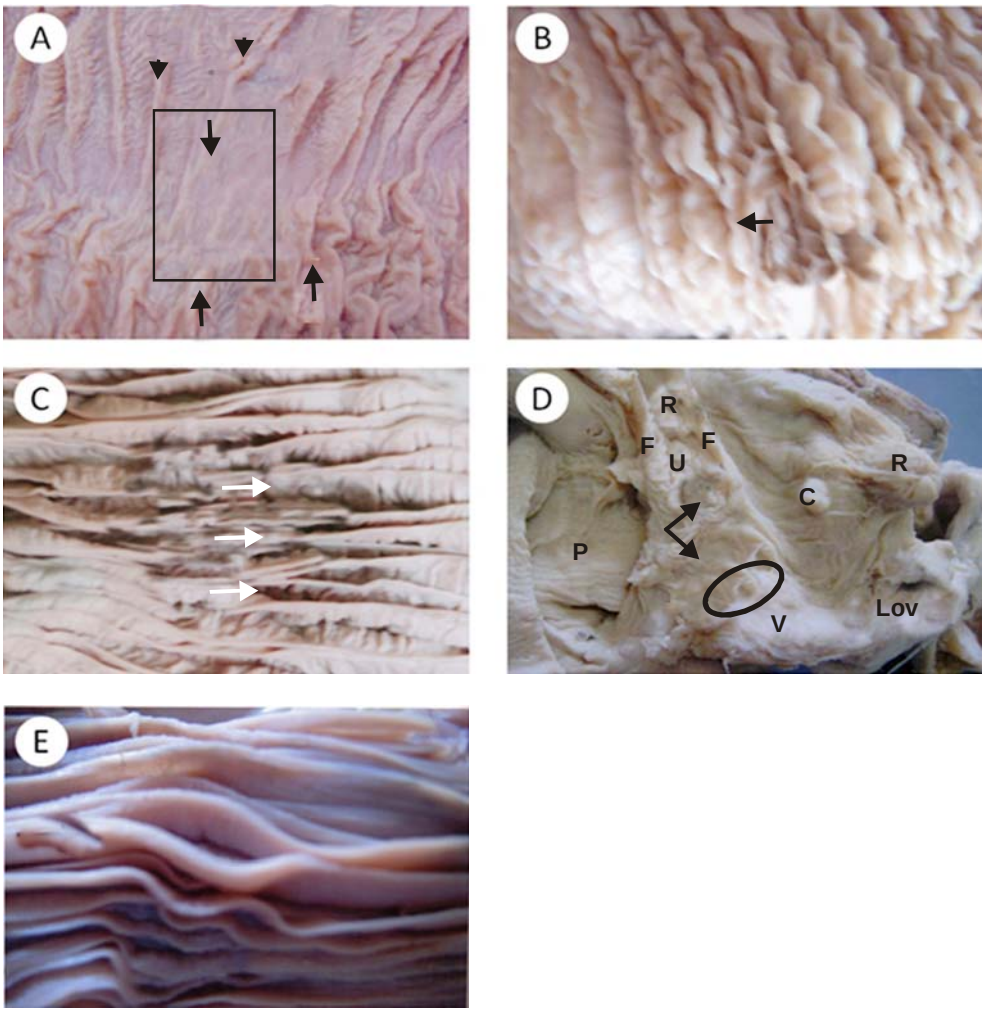

Fig. 1. Gross anatomy of ostrich oviduct **A.** Transition zone between magnum (arrowheads) and isthmus (arrows) called mango-isthmal junction, characterised with very low mucosal folds (square). **B.** Thin and wrinkled uterine mucosal folds of pre-laying ostrich hens (arrow). **C.** Uterine longitudinally arranged tall mucosal folds (uterine lamellae) of laying hens (arrows). **D.** A well-developed membrane between the vagina (V) and urodeum (U) in 3- year-old ostrich hen indicated by (circle). Left oviduct (LOv). The openings of the ureters (arrow), right oviduct appear rudiment (R), urodeum-proctodeum (P), urodeum (U) and coprodeum (C) folds indicated with (F) and rectum (R) are seen. **E.** The vagina of laying ostrich hens has thick tall longitudinally oriented mucosal folds.

in width. The isthmal mucosa contained 31 to 42 longitudinally oriented and corrugated folds. The uterus was differentiated into a cranial short tubal part followed by a varied from 8.0 to 11 cm in width and from 15 to 24 cm in length in laying hens and 3.0 to 5.5 cm in width and 8.5 to 11.5 cm in length in pre-laying

hens. The sac-like part of the uterus was markedly ambulated. It reached 7.0 to 13 cm in length and 10 to 14 cm in width in laying hens. The mucosal folds were greatly increased in height ranging 5.0 to 13 mm. Thus, the uterine mucosal folds were described as uterine lamellae (Fig. 1B, C). Their number ranged from 82 to 104. The free borders of these lamellae were smooth, while their both sides were wrinkled. Most of these lamellae are directed longitudinally, converged towards the vagina.

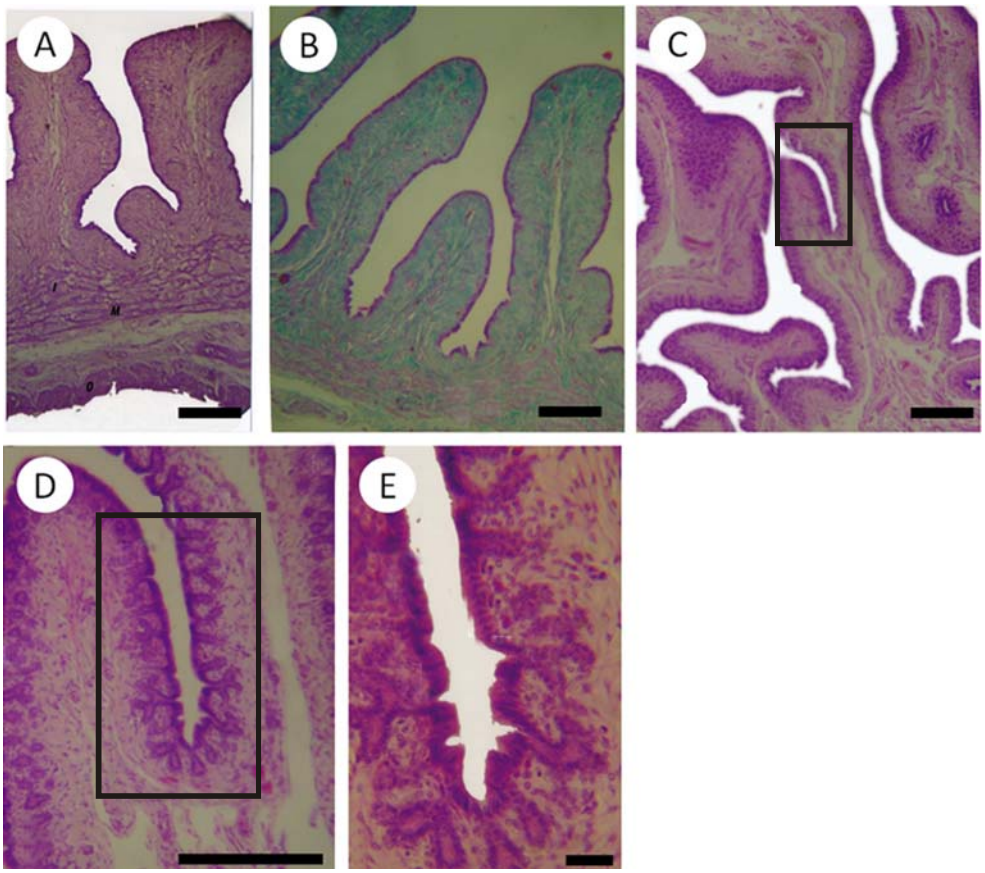

Fig. 2. Isthmus of ostrich. **A.** Isthmus of 15 month-old chicks show primary folds with short ones in between and an inner circular smooth muscle bands, thin outer longitudinal layer of smooth muscle fibres and intermuscular connective tissue. H&E, scale bar 100 µm. **B.** Isthmus of 8-10 month-old ostrich showing collagenic connective tissue in the propria-submucosa and the tunica muscularis. Crossmon's trichrome, scale bar 100 µm. **C.** Isthmus of pre-laying ostrich with irregular primary folds carrying secondary ones and shorter folds in between. H&E, scale bar 100 µm. **D.** Higher magnification of the black square in (C) illustrating tubular glands in the propria open onto the surface epithelium and loose connective tissue submucosa. H&E, scale bar 100 µm. **E.** Higher magnification of the square (D) showing short ciliated pseudostratified columnar epithelium branching and rebranching of proprial glands. H&E, scale bar 20 µm.

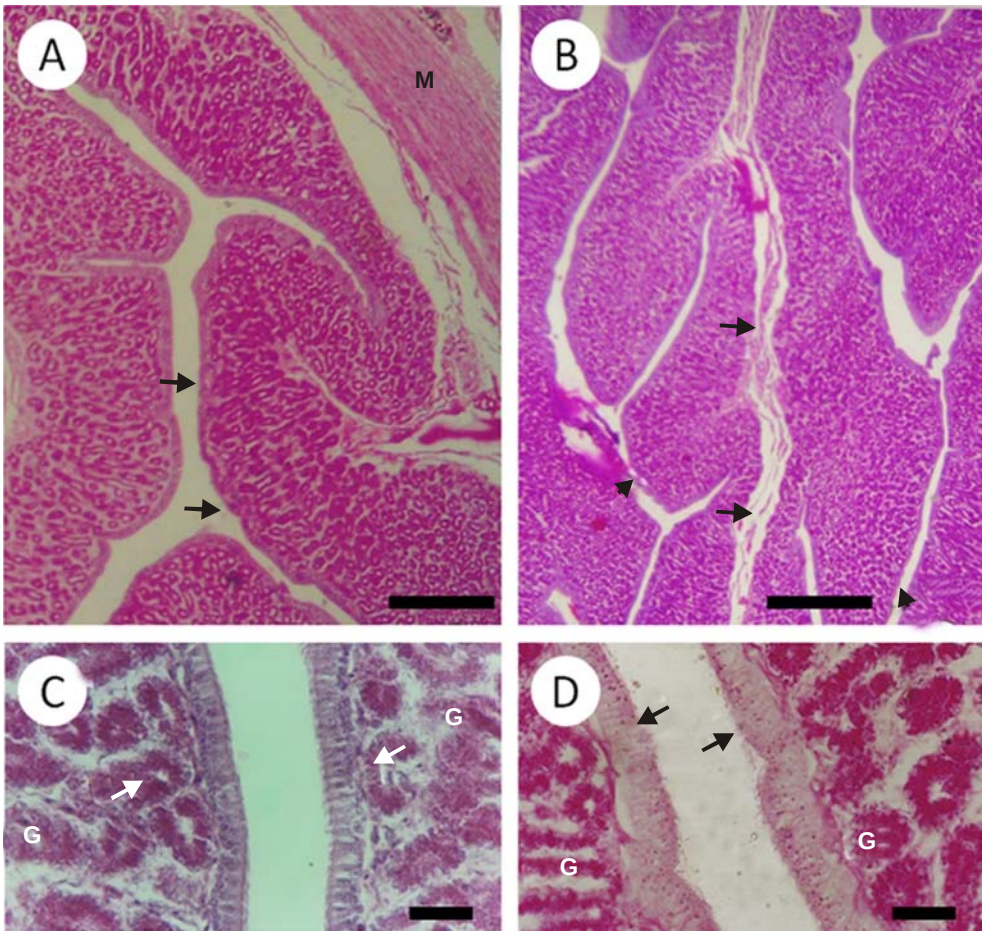

Fig. 3. Isthmus of laying ostrich. **A.** Low and broad mucosal folds (arrow) attached to the inner layer of the isthmal muscular coat (M). H&E, scale bar 200 µm; **B.** Voluminous glandular unites in the isthmus mucosal folds (arrowhead) with central submucosal connective tissue strand (arrow). H&E, scale bar 200 µm. **C.** The surface isthmus epithelium presents pseudostratified columnar epithelium and propria filled with eosinophilic glands (G; arrows). H&E, scale bar 20 µm. **D.** Histochemically, the surface epithelium of the isthmus of laying ostrich hens has scattered PAS-positive granules (arrow) as well as intense PAS-positive staining in the glandular units (G). PAS, scale bar: 20µm.

The vagina was a curved tube opening in the urodeum of the cloaca in laying hens. In pre-laying birds a well developed membrane was found between the vagina and the urodeum. The opening between vagina and cloacae is not present (Fig. 1D).

In laying hens, the length of the vagina varied between 16 to 19 cm and 3.5 to 4.5 cm in width. In pre-laying hens, the vaginal length was 6.0 to 11cm. The vaginal mucosal folds were thin, directed longitudinally, and between 45 to 46 in

number (Fig. 1E). The folds height varied from 2.0 to 5.0 mm.

Histology

In immature birds (8–10 months of age), the mucosa of the isthmus had short primary with lower folds in between. Meanwhile, the mucosa of birds 15 months of age had taller folds (Fig. 2A). The surface epithelium of the isthmus in immature birds was formed of simple columnar cells. The glandular crypts were located in-between the bases of the mucosal folds, lined with the same type of the surface epithelium. The lamina propria was highly cellular and less fibrous containing numerous blood capillaries and delicate collagen fibres (Fig. 2B). The submucosa was formed of loose connective tissue free of glands. Tunica muscularis of the isthmus consisted of two layers; inner network of smooth muscle strands and the outer layer was of longitudinally oriented smooth muscles fibers (Fig. 2A). In the pre-laying birds, the isthmal mucosa was characterised by the presence of irregular primary carrying secondary folds (Fig. 2C). The lining epithelium of the isthmus was formed of short ciliated pseudostratified columnar and simple columnar ciliated and nonciliated variety. It was characterised by the presence of numerous invaginations leading to branched tubular glands in the propria (Fig. 2D). The lamina propria contained simple branched tubular glands. These glands were distributed at the periphery of lamina propria and beneath the covering epithelium of the mucosal folds (Fig, 2E). The glands were connected to the surface epithelium by short ducts (Fig. 2E). In some areas, the number of tubular glands increased gradually to occupy most of the mucosal folds. The submucosa was formed of loose and vascularised connective tissue.

In laying hens, the isthmal mucosa gave long, tortuous primary folds carrying secondary ones and/or several secondary invaginations (Fig. 3A, B). The mucosal folds occupied most of the isthmal lumen leaving narrow clefts. The lining epithelium was of the tall ciliated pseudostratified columnar type. The glands occupied the lamina propria and were lined with columnar cells with rounded basally located nuclei. Their cytoplasm filled with coarse acidophilic granules (Fig. 3C). The submucosa represented with the central core of the folds and formed of fibrous connective tissue mostly containing small blood vessels and smooth muscle cells. In laying hens, the isthmal lining epithelium were contained scattered secretory granules, which were positive to PAS technique. While the supra-nuclear regions of the glandular cells had strong PAS positive reaction (Fig. 3D).

Uterine mucosa of 8–15 month-old birds was characterised by the presence of primary and some occasional secondary folds (Fig. 4A). The lining epithelium was formed of simple columnar cells. The lamina propria-submucosa was cellular less fibrous, containing collagen fibres. Tunica muscularis of the uterus in immature birds (8–10 and 15 month-old) was formed of two layers, a thick inner layer arranged circularly and an outer longitudinal layer of smooth muscle fibres. The uterus was externally covered with serosa. The uterus of pre-laying birds became the most dilated part in the oviduct. Uterine mucosa had thin and long wavy folds carrying secondary ones (Fig. 4B). The epithelium was of the short ciliated pseudostratified columnar type. Lamina propria was formed of delicate connective tissue, containing simple branched alveolar and tubular glands. These

glands were lined with cuboidal or low columnar cells, and opened onto the surface of the mucosal folds via short ducts (Fig. 4B). The submucosa was made of vascular fibrous loose connective tissue. In laying hens, the uterus was differentiated into an anterior short tubular part and a posterior pouch-like portion. The tubular part mucosa was characterised by long primary folds carrying secondary ones and/or several secondary long invaginations (Fig. 4C), while the uterine pouch mucosa had tall primary folds with lateral short secondary ones.

The uterine lining epithelium was of the ciliated pseudostratified columnar type (Fig. 4D, E). The propria harboured long and branched tubular glands, which showed some sort of anastomosis between some adjacent gland tubules (Fig. 4D). These glands were lined with high cuboidal or columnar cells. The interglandular tissue exhibits faint acido-

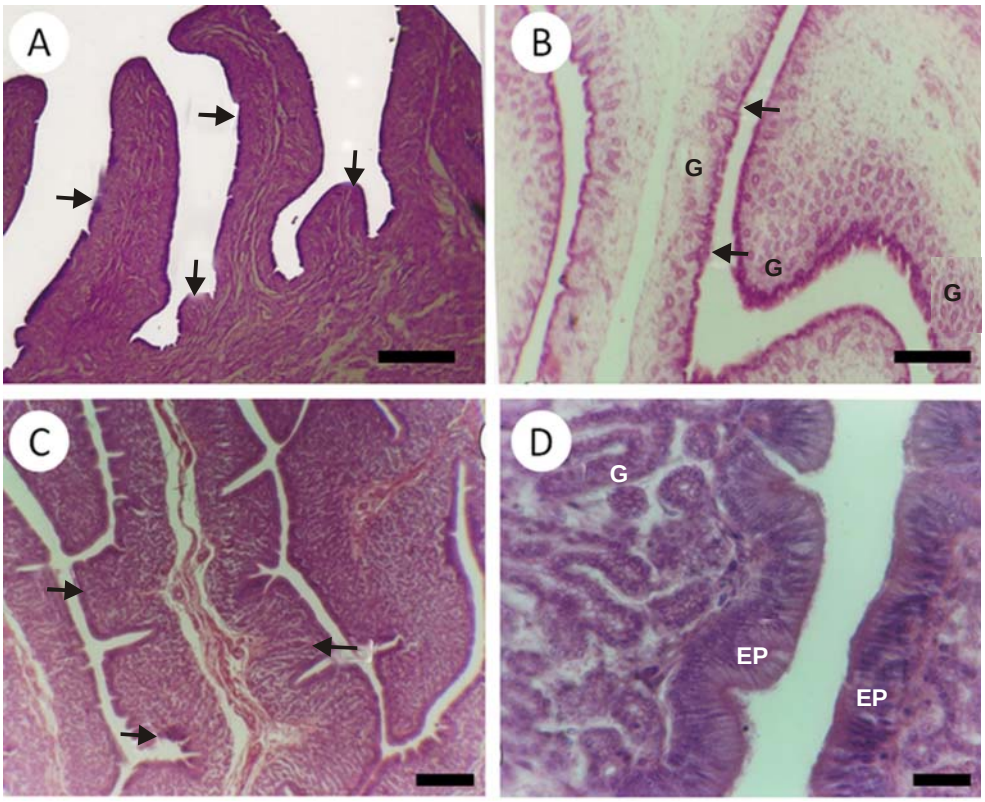

Fig. 4. Ostrich uterus. **A.** Presence of tall primary folds and short ones in-between in a 8-10 months old bird. H&E, scale bar 100 µm. **B.** Prelaying ostrich hens show wavy, narrow folds containing tubular glands (G) under and attached to the surface epithelium (arrow). H&E, scale bar 100 µm. **C.** Tubular part of uterus in laying hens has long primary mucosal folds carrying secondary ones and/or several invaginations (arrow). H&E, scale bar 200 µm. **D.** Propria of tubular part of uterus in laying ostrich hens occupied with long and highly branched tubular glands (G) with anastomosed glandular tubules (H-shaped) and ciliated pseudostratified columnar epithelium (EP). H&E, scale bar 20 µm.

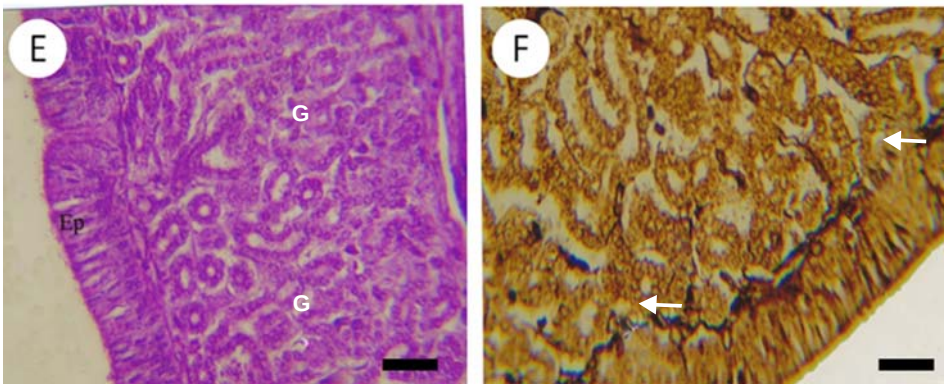

Fig. 4 (cont'd). Ostrich uterus. **E.** Uterine pouch of laying ostrich hens show surface ciliated pseudostratified columnar and massive glands (G) in the propria. H&E, scale bar 20 µm. **F.** Well developed reticular lamina penetrated with ducts of proprial glands (arrow). Silver impregnation technique, scale bar 20 µm.

philic amorphous substance. A well marked reticular lamina was interrupted by the glandular ducts could be observed in silver impregnated paraffin sections (Fig. 4F). In immature chicks (8–10 months of age), the vaginal mucosa gave short and thick primary folds which carry small secondary ones. Meanwhile, in 15 month-old chicks, the mucosa had longer and wavy primary folds. The lining epithelium was of the short ciliated pseudostratified columnar variety. The propria-submucosa was formed of highly cellular, dense collagenic connective tissue. The tunica muscularis of the vagina was formed of thick inner layer arranged circularly and outer longitudinal layer of smooth muscle fibres.

In the pre-laying hens, the vaginal mucosa gave long primary folds carrying few secondary and tertiary ones (Fig. 5A). The lining epithelium was of the ciliated pseudostratified columnar type (Fig. 6B). The cilia formed a continuous ciliary layer above the lining epithelium (Fig. 5B, C). The mucosal folds were separated by wide and long glandular crypts, lined with ciliated pseudostratified columnar epithelium. The cores of the mucosal folds were free of glands and formed of collagenic fibres with the presence of small blood vessels and capillaries. In laying hens, the vaginal mucosa had primary folds carrying extensive secondary and tertiary ones. The lining epithelium increased in height and was formed of tall ciliated pseudostratified columnar epithelium, formed of 3 types of cells: ciliated columnar, nonciliated columnar and basal cells. In laying hens, most of the cytoplasm of the non-ciliated cells of the vaginal epithelium gave positive PAS reaction, which became strong in the apical parts of these cells (Fig. 5D). Furthermore, the lining epithelium was alcianophilic.

Morphometry of the isthmus, uterus and vagina

The different measurements for isthmus, uterus and vagina showed that the vaginal epithelium was the highest as compared with other regions (Table 1). However the isthmal propria was thicker than other

regions (Table 2). The vaginal musculature was the thickest as compared to other oviduct wall regions (Table 3).

DISCUSSION

Ostriches are characterised only with prominent and well developed left oviduct located in the left side of coelomic cavity and it opened directly to the urodeum through the vagina. The right oviduct was rudimented and appeared as vestige in the right side of abdominal cavity which were similar to the same findings of Hodges (1974) in birds; Muwazi *et al.* (1982) in ostrich. The magno-isthmian junction

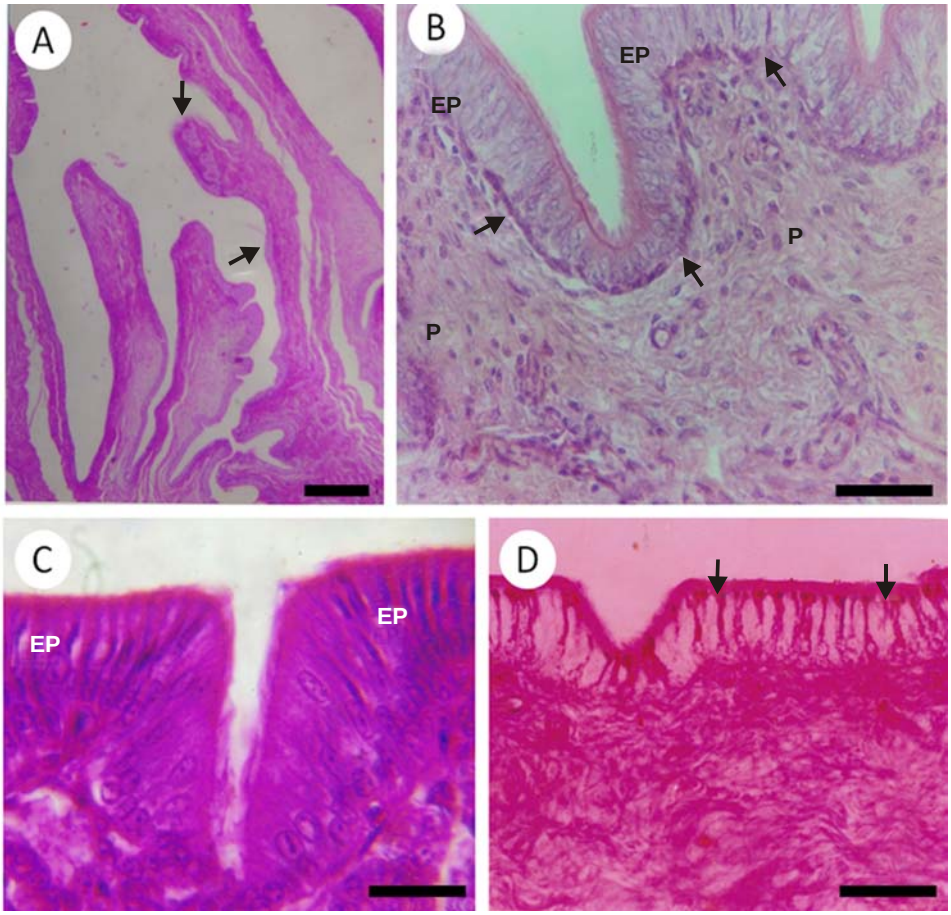

Fig. 5. Ostrich vagina. **A.** Vaginal mucosa of prelaying hens carrying long primary folds with few secondary and tertiary ones (arrows). H&E, scale bar 200 µm. **B.** Vaginal epithelium of tall pseudostratified columanar epithelium (EP) in prelaying hens and clear basal cell layer (arrows) and highly cellular propria-submucosa (P). H&E, scale bar 20 µm**. C.** Higher magnification of the surface epithelium (EP) in B, showing a clear, well developed single basal cell layer (arrow). H&E, scale bar 20 µm. **D.** PAS-positive staining in non-ciliated cells of the vaginal epithelium (arrow). PAS, scale bar 20 µm.

Table 1. Variations in height of the epithelium (μm) lining the different oviducal regions in ostriches with reference to age. Data are presented as mean ± SEM, n=4

Age	Isthmus	Uterus	Vagina
8 months	6.70 ± 0.38[b]	5.10 ± 0.13[b]	8.70 ± 0.89[c]
15 months	8.48 ± 0.54[b]	5.20 ± 0.01[b]	8.48 ± 0.97[c]
36–42 months	10.33 ± 1.30[b]	6.12 ± 0.65[b]	23.87 ± 1.73[b]
60–72 months	18.20 ± 2.31[a]	25.93 ± 1.53[a]	27.48 ± 0.52[a]

means within each column bearing different superscripts are significant at P≤0.05.

Table 2. Variations in thickness of lamina propria (μm) in the oviducal regions in ostriches at different ages. Data are presented as mean ± SEM, n=4

Age	Isthmus	Uterus	Vagina
8 months	93.67 ± 10.80[b]	51.35 ± 4.97[b]	167.66 ± 20.47[b]
15 months	108.76 ± 15.90[b]	73.97 ± 9.24[b]	253.77 ± 13.70[a]
36–42 months	149.53 ± 42.71[b]	120.83 ± 23.84[a]	280.95 ± 11.30[a]
60–72 months	425.93 ± 66.30[a]	172.20 ± 14.93[a]	233.37 ± 11.15[a]

means within each column bearing different superscripts are significant at P≤0.05.

Table 3. Variations in the wall thickness (μm) of different oviducal regions in ostriches at different ages. Data are presented as mean ± SEM, n=4

Age	Isthmus	Uterus	Vagina
8 months	966.7 ± 51.83[c]	1827.5 ± 92.06[d]	3690.8 ± 279.87[d]
15 months	1256.7±30.57[c]	2938.33 ± 181.30[c]	5876.7 ± 286.67[c]
36–42 months	4443.3±212.59[b]	4801.67 ± 205.20[b]	8528.3 ± 375.14[b]
60–72 months	6665.0±595.30[a]	14118.3 ± 489.20[a]	12040.0 ± 368.20[a]

means within each column bearing different superscripts are significant at P≤0.05.

revealed presence of a transitional thin walled zone with very low mucosal folds, this region differentiated the magnum and isthmus as reported by Hodges (1974), Nickel *et al.* (1977), Dellmann & Eurell (1998) in domestic fowls. Our findings were similar to Johnston *et al.* (1963) in Thronber 505 hybrid hens; Hodges (1974), King & Mclelland (1975) in domestic fowls that uterus of the ostrich was subdivided into an anterior short narrow tubular portion and posterior large sac-like portion.

The uterine mucosal folds were markedly increased in height and could be called uterine lamellae, which were reported also by Mclelland (1990) in chickens. In addition, we found that the uterine mucosa was darker in colour than that of vaginal mucosa similar to the results of Bezuidenhout *et al.* (1995) in ostriches. Our work revealed that the uterine lamellae mostly ran longtudinally and appeared to be wrinkled. Moreover, their numbers ranged between 82 and 104. Its height was 5–13 mm while in ostriches Bezuidenhout *et al.* (1995) recorded that uterine mucosa were contained approximately 80 longtudinal folds 5–20 mm in height, with wavy and scapolled appearance. In addition King & Mclelland (1975) found uterine lamellae in domestic

fowls were leaf-like and measured 4 mm in height. Meanwhile, the vaginal mucosa was characterised with thin longtudinally oriented folds as observed by Dellmann & Eurell (1998). Furthermore, in mature ostriches we showed that the vaginal mucosa contained about 45–50 folds measuriing about 2–5 mm in height, contrary to the findings of Bezuidenhout *et al.* (1995) who observed about 80 longitudinally oriented mucosal folds with 5–20 mm height in mature ostriches. The uterus was differentiated from the vagina with the vaginal sphincter and the shape of mucosal folds; the point of transition between uterus and vagina was similar to the findings of Bezuidenhout *et al.* (1995); King & Mclelland (1975); Dellmann & Eurell (1998) in domestic fowl.

Current work revealed the lining epithelium of isthmus, uterus, and vagina were formed of simple columnar and/or ciliated pseudostratified columnar variety. These results agree with those in 1–2 month-old chicks, Fouad (1970) in fayoumi chicks; El-Habbak (1990) in pekin duckling, Elbargeesy (1990) in sexually immature turkeys; Kelany *et al.* (1993) in one day old chicks & Sayed (2000) in 1–3 weeks old quail chicks.

The vaginal epithelium was formed of ciliated pseudostratified columnar epithelium contained both ciliated and non-ciliated columnar secretory cells. These observations were in the same line as recorded by Muwazi *et al.* (1982), Bezuidenhout *et al.* (1995) in mature ostriches; Bakst & Howarth (1975) in domestic fowls; Renden *et al.* (1981) in japanese quail; Hodges (1974) in domestic fowls; Elbargeesy (1990) in sexually mature turkeys, while in domestic ducks, there were no neither goblet cells nor non-ciliated cells in the vaginal epithelium (Das & Biswal 1968).

In the current work, the thickness of lamina propria increased gradually on the expense of the submucosal connective tissue layer to reach its maximum thickness and size in the laying ostrich hens due to the massive increase in the glandular structures. Moreover, in fayoumi fowls Kamel *et al.* (1987) added that the lamina propria in the uterus contained pigment cells, in disagreement with the current findings about lack of pigment cells in the lamina propria of ostrich uterus. This might be due to colourless ostrich eggs.

Magno-isthmian junction and vaginal lamina propria were devoid of glandular structures. These results support the findings of Muwazi *et al.* (1982) in mature ostriches; Prochazkova (1971) in domestic ducks; Verma & Cherms (1964) in board breasted bronze turkey hens; El-Bargeesy (1990) in sexually mature turkeys; El-Habbak (1990) in mature ducks and Sayed (2000) in mature quail. However, tubular glands were found in the beginning of vagina, so Fujii (1963) added that the beginning of the vagina could be distinguished from the rest of the vagina and is called the vaginal gland region.

Kelany *et al.* (1993) found that the isthmian and vaginal glands developed earlier at 6 weeks of age than the development of uterine glands, which developed at 12 weeks of age in Dandarawi-Hy line breed.

The uterine glands were mainly of the simple branched tubular type, similar to the findings of Muwazi *et al.* (1982); Bezuidenhout *et al.* (1995) in mature ostriches, but unlike data provided by Kamel *et al.* (1987) who observed that the uterine glands were formed of branched tubulo-alvealar type that opened into the mucosal surface with short ducts.

The present work detected little acidic and neutral mucopolysaccharides in the uterine epithelium as proved by PAS staning and alcian blue reaction, which disagreed with Johnston *et al.* (1963); Aitken (1971) who found that the uterine epithelium contained only neutral mucopolysaccharides. However, Robinson *et al.* (1968) detected in laying hens acidic mucopolysaccharides in uterine epithelium.

The non-ciliated secretory cells were strongly PAS and alcian blue positive; these cells might be the source of cuticle layer over the egg shell. These findings were similar to those of Chakravati and Sadhu (1959) in laying pigeons and El-Bargeesy (1990) in sexually mature turkeys.

On the contrary, El-Habbak (1990) demonstrated very little amount of neutral mucopolysaccharides in mature ducks. In sexually mature turkeys, a faint alcian blue reaction in the vaginal epithelium was reported (El-Bargeesy, 1990) but A strong alcian blue positive reaction (Guzsal, 1968; Pal, 1977). In addition, Sayed (2000) did not observe neutral mucopolysaccharides in the vagina of early laying quails.

REFERENCES

Aitken, R. N. C., 1971. The oviduct. In: *Physiology and Biochemistry of Domestic Fowl.* vol. 30, ed. D. J. Bell & B. M. Freeman, Academic Press, London, New York, pp. 1237–1289.

Badley, A. R., 1997. Fertility, hatchability and incubation of ostrich (*Struthio camelus*) eggs. *Poultry and Avian Biology Reviews*, **8**, 53–76.

Bakst, M. R., G. Wishart & J. P. Brillard, 1994. Oviducal sperm selection, transport, and storage in poultry. *Poultry Science Reviews*, **5**, 117–143.

Bakst, M. R. & B. Howarth Jr., 1975. SEM preparation and observation of the hen's oviduct. *The Anatomical Record*, **181**, 211–214.

Bezuidenhout, A. J., J. T. Soley, H. B. Groenewald & W. P. Burger, 1995. Sperm storage tubules in the vagina of the ostrich (*Struthio camelus*). *Ondersteeport Journal of Veterinary Research*, **62**,193–199.

Birkhead, T. R., L. Atkin & A. P. Moller, 1987. Copulation behavior of birds. *Behaviour*, **101**, 101–138.

Birkhead, T. R, 1988. Behavioural aspects of sperm competition in birds. *Advances in the Study of Behaviour,* **18**, 35–72.

Bunter, K. L. & H. U. Graser, 2000. Genetic evaluation for Australian Ostriches. Publication No 00/153, Rural Industries Research and Development Corporation.

Chakravarti, K. P. & D. P. Sadhu, 1959. Some aspects of the histochemical studies on the oviduct of the pigeon columba livia Gemlin. In: *Proceedings of the Zoological Society of London*, **12**, 9–14.

Crossmon, G., 1937. A modification of Mallory's connective tissue stains with a discussion of principles involved. *The Anatomical Record*, **69**, 33–38.

Das, L. N. & G. Biswal, 1968. Micro-anatomy of the reproductive tract of domestic duck (*Anas Boscas*). *Indian Veterinary Journal*, **45**, 1003–1009.

Deeming, D. C., 1996. Production, fertility and hatchability of ostrich (*Struthio camelus*) eggs on a farm in the United Kingdom. *Animal Science*, **63**, 329–336.

Deeming, D. C, 1999. The Ostrich: Biology, Production and Health. CAB International, Wallingford, UK, pp: 1–13.

Dellmann, H. D. & J. Eurell, 1998. Textbook of Veterinary Histology, Philadelphia, Paltimore, New York, London. pp. 265–269.

El-Bargeesy, J. H. A, 1990. Studies on the oviduct of laying turkey hens with special reference to its blood supply. Ph. D.

Thesis, Faculty of Veterinary Medicine, Cairo University.

El-Habbak, H. A. M, 1990. Histological and some histochemical studies on the oviduct of Pekin ducks. M.V.Sc. Thesis, Faculty of Veterinary Medicine, Cairo University.

Fouad, S. M., 1970. Histological studies of the female genital system of the Fayoumi fowl broiler and adult. Ph. D. Thesis, Faculty of Veterinary Medicine, Cairo University.

Fujii, S., 1963. Histological and histochemical studies on the oviduct of the domestic fowl with special reference to the region of utero-vaginal junction. *Archivum Histologicum Japonicum,* **3**, 447–459.

Gomori, G., 1937. Silver impregnation of reticulum in paraffin sections. *American Journal of Pathology,* **13**, 993.

Guzsal, E., 1968. Histochemical study of goblet cells of the hen's oviduct. *Acta Veterinaria Academiae Scientiarum Hungaricae*, **18**, 251–256.

Harris, H. F., 1900. On the rapid conversion of haematoxylin into hematin in staining reaction. *Journal of Applied Microscopy*, **3**, 777–781.

Hodges, R. D., 1974. Female reproductive system. In: *The Histology of the Fowl*, part 2. Academic Press, New York, San Francisco, pp. 374–359.

Holm, L. S, D. Ruziwa, V. Dantzer, & Y. Ridderstrole, 2000. Carbonic anhydrase in the utero-vaginal junction of immature and mature ostriches. *British Poultry Science*, **41**, 244–249.

Johnston, H. S., R. N. C. Aitken & G. M. Wyburn, 1963. The fine structure of the uterus of domestic fowl. *Journal of Anatomy (London),* **97**, 333–344.

Kamel, G., A. H. S. Hassan, A. M. A. Ali & A. Nafady, 1987. Light and scanning electron microscopical observation on the shell gland of fayoumi fowl. *Assiut Veterinary Journal,* **18**, 58–62.

Kelany, A. M., S. A. El-Shamy, A. Abou-El-Magd, A. A. Selim, G. Kamel & M. R. Fath-El-Bab, 1993. Studies on the development of the oviduct in high and low egg producing fowl. II. Histological studies. *Assiut Veterinary Journal*, **28**, 27–36.

King, A. S. & J. Mclelland, 1975. Outlines of Avian Anatomy. Bailliere Tindall, London.

Lake P. E, 1975. Gamete production and the fertile period with particular reference to domesticated birds. *Symposia of the Zoological Society of London,* **35**, 225-244.

Malecki I. A & G. B Martin, 2002. Fertile period and clutch size in the emu (*Dromaius novaehollandiae*). *Emu*, **102**, 165–170.

Malecki, I. A. & G. B. Martin, 2003. Sperm supply and egg fertilization in the ostrich (Struthio camelus). *Reproduction in Domestic Animals*, **38**, 429–435.

Mclelland, J., 1990. A Colour Atlas of Avian Anatomy, Edinburgh, Scotland, pp. 66–73.

Muwazi, R. T., J. Baranga, F. I. B. Kayanja, & Schliemamm, 1982. The oviduct of the ostrich *Struthio camelus massaicus*. *Journal of Ornithology,* **123**, 425–433.

Nickel, R., A. Schummer, & E. Seiferle, 1977. Anatomy of Domestic Birds. Verlag Paul Parey, Berlin. Humburg, pp. 95–99.

Pal, D., 1971. Histochemistry of the utero vaginal junction with special reference to the sperm host glands in the oviduct of the domestic duck. *Folia Histochemica et Cytochemica (Krakow),* **15**, 235–242.

Prochazkova, E., 1971. Histological observation on post incubation development of oviduct glands in *Gallus domesticus*. III – Development of uterus. *Anatomischer Anzeiger (Jena),* **129**, 105–113.

Renden, J. A., E. B. May & F. H. Benoff, 1981. Histochemistry of utero vaginal sperm-host gland in Japanese quail (*Coturnix coturnix japonica*) with reference to the period of oviposition. *Poultry Science*, **60**, 2529–2535.

Robinson, D. S., N. R. King & D. J. Bowen, 1968. The occurrence of neutral and acidic

mucin in the reproductive tract of laying hen. *Histochemistry*, **13**, 97–104.

Sayed, A. H. A., 2000. Post-hatching development of the pars distalis of the adenohypophysis of the quail (*Coturnix coturnix*) in relation to the oviduct. Ph. D. Thesis, Faculty of Veterinary Medicine, Cairo University.

Sharaf, A., W. Eid & A. Abuel-Atta, 2012. Morphological aspects of the ostrich infundibulum and magnum. *Bulgarian Journal of Veterinary Medicine*, **15**, 145–159.

Steedman, H. F., 1950. Alcian blue 8GS. A new stain for mucin. *Quarterly Journal of Microscopic Science,* **91**, 477–490.

Verma, O. P. & F. L. Cherms, 1964. Observation on the oviduct of turkeys. *Avian Diseases*, **8**, 19–26.

Paper received 17.12.2012; accepted for publication 18.03.2013

Correspondence:

Dr. Ahmed Sharaf
Department of Histology and Cytology,
Faculty of Veterinary Medicine,
Zagazig University, 44519 Zagazig, Egypt
e-mail: ahmed_vet77@yahoo.com