



PREGNANCY TOXAEMIA IN A FRENCH BULLDOG DUE TO EXTREMELY LARGE FETAL NUMBER: A CASE REPORT

A. ANTONOV

Department of Obstetrics, Reproduction and Reproductive Disorders, Faculty of Veterinary Medicine, Trakia University, Stara Zagora, Bulgaria

Summary

Antonov, A., 2023. Pregnancy toxaemia in a French bulldog due to extremely large fetal number: A case report. *Bulg. J. Vet. Med.*, **26**, No 1, 128–132.

The aim of this report was to describe a clinical case of pregnancy toxaemia in a bitch in the late gestational phase. The patient was presented 61 days after the last mating with an extreme abdominal distension, depression, prostration, apathy, vomiting, anorexia, dehydration, dyspnea and without any labour signs. Ultrasonography revealed fetal distress and laboratory analysis showed anaemia, hypoglycaemia and ketonuria, so diagnosis of pregnancy toxaemia was made. Caesarean section was performed and 13 live puppies were born. In conclusion, this is a very rare case of toxaemia during gestation period in a bitch caused by the large number of fetuses.

Key words: bitch, Caesarean section, pregnancy toxaemia

Several diseases in the bitch, which could develop during pregnancy as a consequence of the pregnancy itself are described in the literature including pregnancy toxaemia, diabetes mellitus, eclampsia and hypertension (Lamm & Makloski, 2012). Pregnancy toxaemia is a metabolic disorder, characterised by hypoglycaemia and ketonaemia as a result of the inability of the animal to maintain adequate energy balance associated with increased corporal fat mobilisation to meet energy requirements. The condition is well recognised in sheep as pregnancy toxaemia and in women as preeclampsia,

but is uncommon in bitches (Neta *et al.*, 2018). Bitches with inadequate carbohydrate intake, especially these with large litters, have an increased potential to develop this kind of gestational toxaemia, which is life threatening for both the dam and the offspring (Johnston *et al.*, 2001).

This case report presents a very rare pregnancy toxaemia as a complication of extremely large number of fetuses in a bitch.

Case description

A 3-year-old, multiparous French Bulldog bitch, weighing 13.8 kg, was presented to

the Small Animal Clinic of the Faculty of Veterinary Medicine, Trakia University in Stara Zagora with signs of extreme abdominal distension, depression, prostration, apathy, vomiting, anorexia, dehydration, dyspnea, without lactation and labour signs. The owner reported that these signs appeared spontaneously 2 days ago and the patient has had two previous normal parturitions with litters of 10 and 8 puppies, respectively.

On physical examination, there were changes in the general condition of the animal: rectal body temperature 37.6 °C, heart rate 132 min⁻¹, respiratory rate 82 min⁻¹. The colour of visible mucous coats was rose-red.

At inspection, the abdomen was very distended (Fig. 1). The vulva was oedematous and without any discharge. Transabdominal ultrasonography (Mindray DC-6 Vet, China, 6.5 MHz convex transducer) revealed a presence of fetal distress.

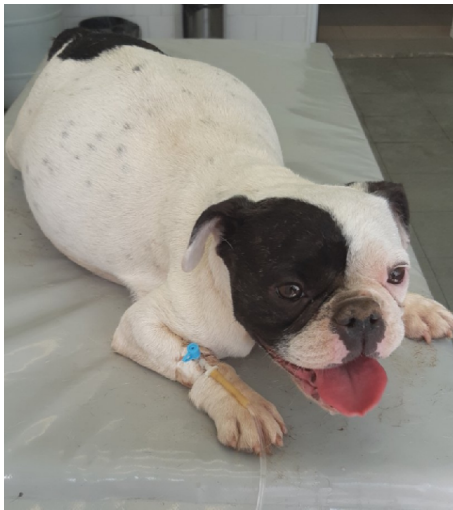

Fig. 1. The patient at the presentation at the clinic.

To determine complete blood cell counts and biochemical parameters, blood

samples (~1 mL) were collected by venipuncture of the cephalic vein. Complete blood cell counts were assayed on an automated haematological analyser BC-2800 Vet (Mindray, China), and blood biochemical parameters – on an automated biochemical analyser BS 120 (Mindray, China). Blood laboratory analysis showed the presence of anaemia, thrombocytosis, hypoglycaemia, increased AST and urea (Table 1). Ketonuria (++) was detected by urinalysis reagent tape UroColortm 10.

The patient was diagnosed with pregnancy toxæmia, so a decision for Caesarean section was taken. In order to determine if the pregnancy was at term, blood serum progesterone was assayed using a Progesterone ELISA kit (Dialab, Austria). The test used a competitive sandwich ELISA for quantitation of progesterone in biological fluids and sample concentrations were calculated from the standard curve in ng/mL. Thus, the blood progesterone of the patient was 2.61 ng/mL, therefore we recommended to the owner emergency operation after intravenous administration of 40% glucose to the patient at the dose of 1.0 mL/kg.

After aseptic preparation of the abdominal region, the bitch was premedicated by 0.04 mg/kg atropine sulphate (Atropinum sulfuricum; Sopharma; Bulgaria) subcutaneously. Fifteen minutes later, anaesthesia was induced by intravenous injection of 5 mg/kg propofol (Propofol; Claris Lifesciences UK Limited; United Kingdom). After endotracheal intubation, general anaesthesia was maintained with isoflurane (Forane; Abbott Laboratories Ltd; United Kingdom). The bitch was placed in a dorsal recumbency with elevated cranial part of the body and a caudal median laparotomy was performed. Gross examination of the ab-

Table 1. Patient's haematological and blood biochemistry analysis results

Haematology	Result	Reference values*	Biochemistry	Result	Reference values**
Haemoglobin (g/L)	106	120–180	Alkaline phosphatase (U/L)	75	20–156
Haematocrit (%)	29	37–55	Glucose (mmol/L)	3.0	3.61–6.55
Red blood cells (T/L)	3.95	5.5–8.5	AST (U/I)	334	23–66
White blood cells (G/L)	13.81	6.0–17.0	ALT (U/L)	65	21–102
Platelets (G/L)	699	200–500	Urea (mmol/L)	8.3	1.67–3.33
MCV (fL)	73.4	60–77	Creatinine (µmol/L)	88	44.2–132.6

*Weiss & Wardrop (2010); **Kaneko et al. (2008); AST: aspartate aminotransferase; ALT: alanine aminotransferase.



Fig. 2. Thirteen live French Bulldog puppies after the Caesarean section.

dominal cavity revealed very enlarged uterine horns. Incision of the uterine body was made dorsally and 13 live puppies were removed from the uterine cavity (Fig. 2), which was closed using USP 2/0 polyglycolic acid absorbable sutures (Marlin; Catgut GmbH; Markneukirchen). Inspection of the abdominal organs revealed hepatic lipidosis (Fig. 3). The ab-

dominal cavity was closed with cross stitch pattern using USP 2/0 polyglycolic acid absorbable sutures (Marlin; Catgut GmbH; Markneukirchen) and the skin was sutured with simple interrupted non-absorbable sutures USP 2/0 (Vitalon; Dr Hammer & Co. GmbH; Hamburg).

Postoperative treatment included antibiotic – 8.75 mg/kg amoxicillin-clavula-

nic acid (Synulox RTU; Zoetis; Belgium),

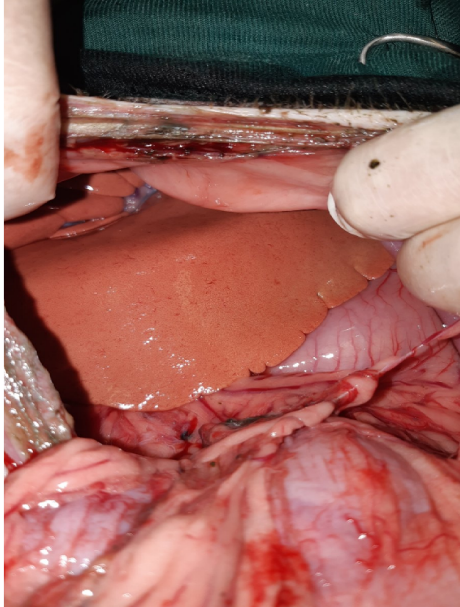


Fig. 3. Intraoperative appearance of the liver of the patient.

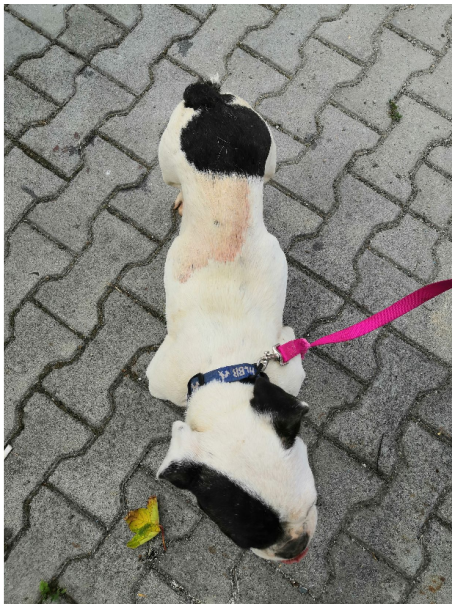


Fig. 4. The patient at the day after the Caesarean section.

subcutaneously for 5 days, correction of dehydration using Ringer lactate and 10% glucose at the dose of 5.0 mL/kg for 3 days.

Because of the absence of lactation, the owner was recommended to use lyophilised neonatal milk for puppies. At the day after the operation, patient had a moderate appetite and was able to move independently (Fig. 4).

Skin sutures were removed after 10 days. The post-operative examination showed total absence of lactation, but the patient was in a good condition. The owner reported that 3 of the puppies died during the first 24 hours after the operation and the others were growing normally.

Pregnancy toxæmia is an uncommon condition in bitches (Root Kustritz, 2019), caused by altered carbohydrate metabolism in late gestation, resulting in ketonuria without glycosuria or hyperglycaemia. The commonest cause is poor nutrition or anorexia during the second half of gestation (Nelson & Guillermo Couto, 2020). In this case, because of excessively large litter, the bitch probably had difficulty eating due to the compression of the stomach. In our opinion, this is the reason for occurrence of the condition. During gestation there is an intense energy consumption for providing the uterine and fetal development, but pregnancy hypoglycaemia in bitches is a rare condition, since progesterone normally acts as a potent insulin antagonist, reducing the transport of glucose into the cell, resulting in hyperglycaemia (Neta *et al.*, 2018). If the bitch does not take enough calories, her body starts mobilisation of stored fat and the release of fatty acids and ketones, which are toxic and worsen lack of appetite and depression (Root Kustritz, 2019).

There is an increased risk of stillbirths in bitches with pregnancy toxemia. In our case, all the newborns were alive and only 3 of the them died during the first 24 hours after the Caesarean section, may be because of the fetal distress diagnosed by ultrasonography. An improved plan of nutrition could resolve the condition in most of the cases, but in severe cases termination of pregnancy may be indicated (Nelson & Guillermo Couto, 2020) to permit the bitch to normalise metabolism without the burden of the fetuses (Root Kustritz, 2010). Despite the low sensitivity of a single serum progesterone determination (Rota *et al.*, 2015), the patient's levels correctly indicated that the pregnancy was at term. Additional evidence for this was the survival of almost all the puppies. The bitch resolved the condition completely after the operation, because the removing of the fetuses gives a chance for immediate metabolic correction of the mother (Nelson & Guillermo Couto, 2020).

REFERENCES

- Johnston, S., M. Root Kustritz & P. Olson, 2001. Canine pregnancy. In: *Canine and Feline Theriogenology*. W. B. Saunders, Philadelphia.
- Kaneko, J., J. Harvey & M. Bruss, 2008. *Clinical Biochemistry of Domestic Animals*, 6th edn, Saunders, Philadelphia.
- Lamm, C. & C. Makloski, 2012. Small Animal Theriogenology. *Veterinary Clinics of North America: Small Animal Practice*, **42**, 451.
- Nelson, R. & C. Guillermo Couto, 2020. *Small Animal Internal Medicine*, 6th edn, Elsevier.
- Neta, J., L. Trautwein, & M. Mello Martins, 2018. Hipoglicemia associada à cetose em cadelas na fase final de gestação. *Acta Scientiae Veterinariae*, **46**, Suppl. 1, 269.
- Root Kustritz, M., 2019. *The Dog Breeder's Guide to Successful Breeding and Health Management*. Cambridge Scholar Publishing.
- Root Kustritz, M., 2010. *Clinical Canine and Feline Reproduction: Evidence-Based Answers*. Wiley-Blackwell.
- Rota, A., C. Charles, A. Starvaggi Cucuzza & P. Pregel, 2015. Diagnostic efficacy of a single progesterone determination to assess full-term pregnancy in the bitch. *Reproduction of Domestic Animals*, **50**, 1028–1031.
- Weiss, D. & K. Wardrop, 2010. *Schalm's Veterinary Hematology*, 6th edn, Blackwell Publishing, Iowa.

Paper received 28.07.2020; accepted for publication 18.09.2020

Correspondence:

Anton Lazarinov Antonov
Department of Obstetrics, Reproduction and Reproductive Disorders,
Faculty of Veterinary Medicine,
Trakia University,
6000 Stara Zagora, Bulgaria,
tel: (+359) 42 699 514
e-mail: anton.antonov@abv.bg