



ACQUIRED NON-INCARCERATED INGUINAL/SCROTAL HERNIATION IN WORKING DONKEYS (*EQUUS ASINUS*)

M. A. MARZOK^{1,2} & A. M. MOUSTAFA¹

¹Department of Veterinary Surgery, Anesthesiology and Radiology, Faculty of Veterinary Medicine, Kafrelshiekh University, Egypt; ²Department of Clinical Science, Faculty of Veterinary Medicine, King Faisal University, KSA

Summary

Marzok, M. A. & A. M. Moustafa, 2023. Acquired non-incarcerated inguinal/scrotal herniation in working donkeys (*Equus asinus*). *Bulg. J. Vet. Med.*, **26**, No 2, 280–288.

In equine practice, inguinal hernia is a common disease and can be either acquired (direct) or congenital (indirect). This retrospective study aimed to describe the presentation and surgical management of acquired inguinal/scrotal herniation in 11 working donkeys (nine intact males, one gelding, and one female). All donkeys had a unilateral acquired inguinal/scrotal hernia, which was noticed by the owner for a period of two to 24 weeks. All the swellings were reducible, painless, not accompanied by an acute abdomen. Ultrasonography, rectal, and clinical examination are useful tools for the diagnosis of inguinal/scrotal hernias in donkeys. Eight animals underwent successful inguinal herniorrhaphy with the removal of the testicle at the affected side, and the superficial inguinal ring was closed by application double-layer polypropylene mesh. The recovery period ranged from 14 to 25 days (average, 16.8 ± 2.8 days). All donkeys released from the clinic returned to their previous levels of exercise. Our study showed that acquired inguinal or scrotal herniation in donkeys is not a clinical emergency requiring prompt intervention. To the best of our knowledge, this is the first report describing this condition in donkeys.

Key words: acquired, donkeys, inguinal hernia, scrotal hernia

An inguinal herniation is a common horse disease with a highly noticeable clinical symptomology characterised by protrusion of an abdominal viscus through the vaginal ring into the vaginal process with a descent into the inguinal canal or extended into the scrotum (Schneider *et al.*, 1982; Cox, 1988). Therefore, the terms scrotal and inguinal herniation have been

used correspondently (Mezerová *et al.*, 2003). In most cases of equine inguinal/scrotal herniation, the hernial sac most often contains a small intestine. However, herniation of the large intestine, omentum, or urinary bladder has also been reported (Ivens *et al.*, 2009; Robinson & Carmalt, 2009; Cousty *et al.*, 2010). Equine inguinal/scrotal herniation can be either ac-

quired or congenital. An acquired hernia is the most common form of inguinal hernia seen in adult male horse and is usually unilateral, incarcerated (irreducible) or strangulated, and accompanied by signs of abdominal pain (moderate to severe colic) (Huskamp & Kopf, 1997). In contrast, congenital herniation primarily occurs in new-born colt foals and is relatively uncommon, usually bilateral, non-incarcerated (reducible), and not accompanied by signs of colic (Spurlock & Robertson, 1988).

Acquired hernias in the donkey are most commonly reported at the ventrolateral abdominal wall and are more commonly traumatic in origin (Misk, 1984). The available veterinary literature has described the different types of inguinal/scrotal herniation in horses (Schneider *et al.*, 1982; Weaver, 1987; van der Velden & Stolk 1990, Moll *et al.*, 1991; Huskamp & Kopf, 1997) but no previous reports, to the best of the authors' knowledge, have been recorded in the domesticated donkey (*Equus asinus*). In this report, we describe the presentation and surgical management of acquired inguinal/scrotal herniation in working donkeys.

During the period from 2016 to 2019, 11 donkeys (nine intact males, one gelding, and one female) with a mean \pm SD weight of 217 ± 10.1 kg from different localities (Kafrelsheikh, Gharbiah, and Domiat governments) were admitted to the Veterinary Teaching Hospital, Kafrelsheikh University, Egypt. The age of the donkeys was ranging approximately from three to nine years, with an average age of 6.4 years. All donkeys were found to have a large swelling in the scrotum in males or near the groin in females (Fig. 1). The history of all cases indicated that the inguinal swellings were noticed by the owner for a period of 2 to 24 weeks. The

gelding presented in this series had been castrated 1 year before herniation occurred. These donkeys had no signs of previous colic symptoms. All cases came to the clinic in the summer (dry season). The cases were presented either with an established diagnosis by a referring veterinarian ($n=2$) or diagnosed at the veterinary teaching hospital ($n=9$). In all cases, the history given by the owners was a sudden appearance of swellings and the affected side was not equally distributed (eight left and three right).

All donkeys were clinically checked (rectal temperature, heart and respiratory rate, palpation, rectal and ultrasonographic examination) and laboratory data (total plasma protein, haematocrit, leukocyte count, blood pH, base excess, bicarbonate concentration) were collected immediately upon arrival to the veterinary hospital. All donkeys were considered healthy enough to undergo surgical repair of the inguinal or scrotal herniation. Clinical examination revealed that all patients were bright and alert, and with a fair body condition, with normal rectal temperature, pulse, and respiration. Palpation of the scrotum in all cases revealed a large painless form of fluctuating reducible swelling (Fig. 2), a sensation of crepitus, movement of scrotal skin due to peristalsis of the entrapped intestine, and none of the donkeys reacted to deep palpation of the swelling. Upon rectal examination of 8 donkeys (in three donkeys this was not performed), a small intestinal loop was palpated entering the inguinal canal through the vaginal ring. Moreover, the slit-like opening of the vaginal ring in the affected side was wider than the normal side, and the examiner was able to insert more than two fingers into the inguinal canal.



Fig. 1. An entire male donkey (A), gelding (B) and female donkey (C) with an acquired left-sided inguinal/scrotal hernia.

The percutaneous scrotal or inguinal region ultrasonography showed an intestinal loop that had moved into the scrotal cavity close to the testicle (Fig. 3). B-mode ultrasonographic images of the scrotum provided valuable information regarding the testis and the motility or viability of the herniated intestine. The testicle of the affected side was less echogenic than its normal counterpart. Addi-

tionally, in two animals the scrotal ultrasonography showed some free fluid content suggestive of hydrocele.

According to the owner's request, three cases (one female and two intact males) received no surgical interference due to financial difficulties. Seven intact males and one gelding underwent successful inguinal herniorrhaphy under general anaesthesia in dorsolateral recumbency.

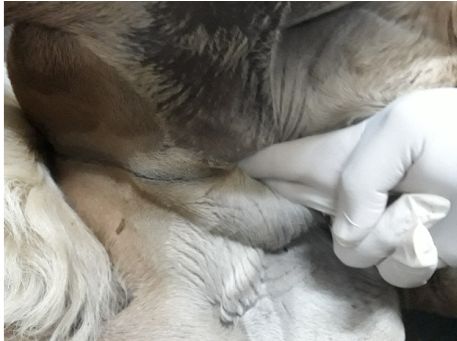

Fig. 2. Palpation of the superficial inguinal ring showing a reducible swelling in which the herniated intestine manually descended through the inguinal canal into the abdominal cavity.

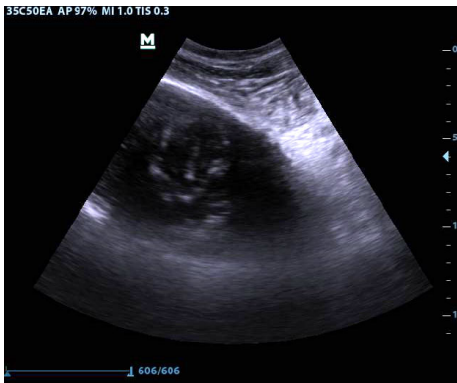

Fig. 3. Ultrasonographic image of the scrotal herniation in a gelding donkey. Note the appearance of the intestine in the scrotal sac.

Before herniorrhaphy, all cases were administered intravenously 22,000 IU/kg body weight sodium penicillin (Penicillin G sodium; Sandoz), 6.6 mg/kg gentamicin sulphate (Garamycin; Schering-Plough), and 1.1 mg/kg flunixin meglumine (Finadyne; Schering-Plough Animal Health). The donkeys were sedated using 0.8 mg/kg xylazine HCL (Xylaject; Adwia, Egypt) and 0.03 mg/kg butorphanol (Torbugesic; Zoetis), both administered intravenously. Anaesthesia was induced with 0.05 mg/kg diazepam (Valium; Roche)

and 2.5 mg/kg ketamine (Ketaset; Zoetis) given intravenously, and the donkeys were intubated and maintained on isoflurane (Isoflo; Abbott) vaporised in 100% oxygen, using a large animal circle system. During the surgery, every donkey received intravenous fluids, and the arterial blood pressure was monitored.

The primary repair of an inguinal hernia was performed successfully by inguinal herniorrhaphy. In all cases, the small intestine (ileum or distal jejunum) was visualised through the vaginal cavity. During surgical interference, only the small intestinal reposition and occasionally decompression of the small intestine herniated loop was also performed in most donkeys with acquired inguinal hernias.

Each donkey was placed in dorso-lateral recumbency, and the affected inguinal area was clipped and aseptically prepared for surgery. The hindleg on the affected side was uppermost and secured in flexion and abduction. A 10 cm long incision was made from the cranial edge of the superficial inguinal ring to the distal aspect of the scrotum through the skin, subcutaneous tissue, and scrotal fascia. After carefully dissecting the testicle and the vaginal sac with its contents from the scrotum, the parietal vaginal tunic was incised carefully to expose the herniated loop of the small intestine contained within (Fig. 4). The herniated intestine was gently replaced by digital pressure into the abdomen through the vaginal ring. The testicle on the affected side was then drawn outside the vaginal cavity. The spermatic cord and vaginal sac were removed after crushing, ligation, and transection of the vaginal sac and spermatic cord approximately 2 cm distal to the ligature. The superficial inguinal ring was closed by application of double-layer polypropylene mesh (Prolene, Johnson and

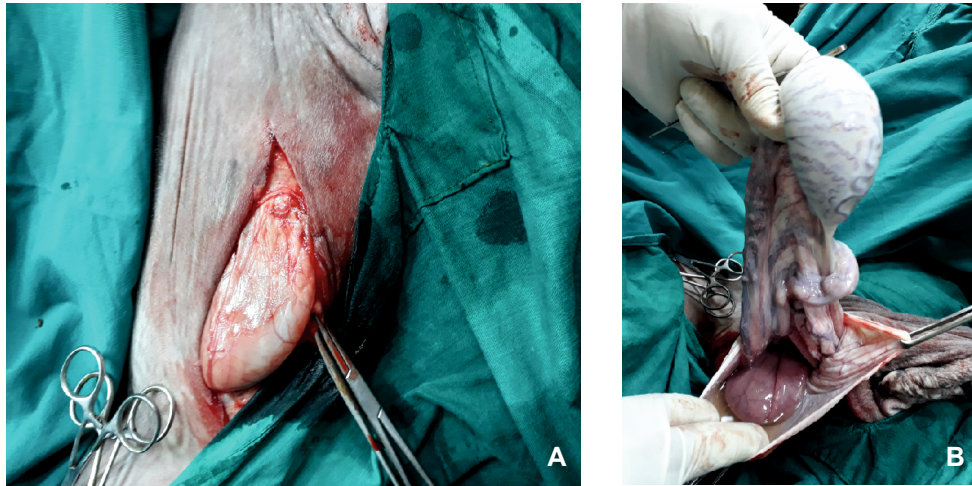


Fig. 4. **A)** The vaginal sac with its content after incision the the cranial edge of the superficial inguinal ring to the distal aspect of the scrotum; **B)** The affected testicle and herniated loop of the small intestine after the incision of the parietal vaginal tunic.

Johnson). The mesh was sutured to the superficial inguinal ring using pre-placed 4 metric polyglactin 910 (Vicryl; Johnson and Johnson) in a simple interrupted pattern (Fig. 5). These sutures were placed 1.5 cm from the edges of the superficial inguinal ring. A drain was placed in the wound and finally (Fig. 6) the skin was closed with 3 metric polydioxanone (PDS; Johnson and Johnson) in a simple interrupted pattern.

All patients recovered from general anaesthesia after surgery and all cases were monitored intensively, and tetanus prophylaxis was provided. The antimicrobial cover (sodium penicillin and gentamicin sulphate) and flunixin meglumine was continued for 7 days. The donkeys were offered a soft diet on the first week after surgery and kept two days of box rest followed by seven days of hand walking twice daily. Scrotal swelling associated with oedema formation occurred in three donkeys. Oedematous swelling and purulent discharge were observed from the

incision wound five days postoperatively in one donkey, but was treated successfully by conservative methods. Follow up information was collected by telephone contact with veterinarians. The recovery period ranged from 14 to 25 days (average, 16.8 ± 2.8 days). All donkeys released from the clinic returned to their previous levels of exercise 3–6 months following discharge.

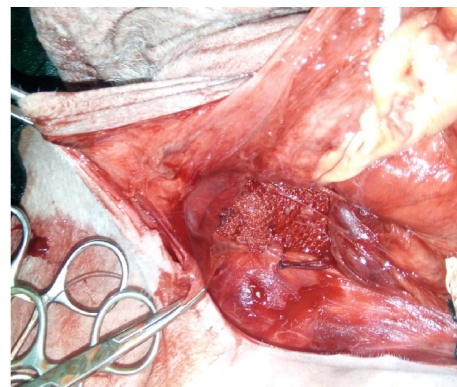


Fig. 5. Repair of an inguinal/scrotal hernia in a male donkey, showing the polypropylene mesh after tightening of the sutures.

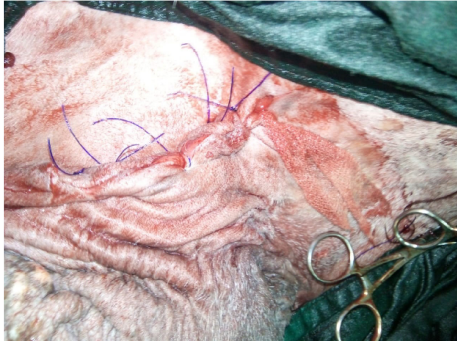

Fig. 6. Postoperative appearance of the inguinal area after correction of the hernia. The last stitch of the superficial inguinal ring incision was not knotted and a drain was applied through it to allow drainage of exudates.

In equine practice, acquired inguinal hernia is a common lesion in horses and is considered the second most frequent type after umbilical hernia diagnosed in these animals. There is no available report for this type of hernia in donkeys. Therefore, the goal of the present case series was to describe the presentation and surgical management of acquired inguinal/scrotal herniation for the first time in 11 working donkeys.

In the horse, every acquired inguinal or scrotal hernia is a serious life-threatening emergency condition (Spurlock & Robertson, 1988; Mezerová *et al.*, 2003). The herniated intestine often becomes incarcerated or strangulated, resulting in acute colic pain. Herniated intestine strangulation is caused by the vaginal ring constriction of the bowel (Schumacher & Perkins, 2010). Interestingly, the results of our study showed that all acquired inguinal herniation in donkeys was without serious condition than in horse and does not represent emergency treatment. All the inguinal swellings were reducible, painless, not accompanied by an acute abdomen.

The anatomical feature of the inguinal canal is responsible for the development and incarceration of the inguinal hernia in horses. The inguinal canal is a natural body orifice bordered by superficial and deep inguinal rings, and the exit into the inguinal canal is through a slit opening of the peritoneum called the vaginal ring (Sisson & Grossman, 1953). The size of the vaginal ring to the anatomical structures it passes determines if the hernia is strangulating or not. The diameter of the vaginal ring differs between the horses of different breeds and between the individual horses of the same breed but usually is large enough to allow the entry of normal testicular structures. The vaginal ring is occasionally large sufficient for the small intestine to herniate into the vaginal tunic, where the intestine descends into the inguinal canal or the scrotum along the spermatic cord. Incarceration of the herniated intestine is typically situated about 2–3 cm away from the funnel-shaped vaginal ring, where the inguinal canal narrows in an hour-glass-like fashion (Kersjes *et al.*, 1985; Kovač *et al.*, 2018). In the current study, it has been shown that all examined donkeys were presented with long-standing reducible acquired inguinal hernias, and none of them had incarcerated or non-viable (strangulated) small intestine. The present result may be probably attributed to the abnormal wide diameter of both the inguinal canal and the vaginal ring in all affected donkeys. Although in the available veterinary literature, there is no report about the anatomical feature of the inguinal canal in donkeys, our hypothesis is supported by the rectal palpation findings which showed that all vaginal rings of the affected sides were wider than the normal sides. A vaginal ring that freely allows more than two fingers to pass should be

considered enlarged and the donkey at risk for developing an inguinal or scrotal hernia.

Inguinal/scrotal hernia in horses has been classified as unilateral or bilateral, congenital or acquired, indirect, or direct. In this study, all the donkeys were presented with unilateral inguinal herniation, which occurred more commonly on the left side. These findings were similar to those reported in horses (Hutchins & Rawlinson, 1972). Congenital inguinal hernias usually occur in newborn male foals and are usually reducible and painless (Schumacher & Perkins 2010). In the current study, we reported only acquired inguinal hernias in the inguinal region of adult working donkeys. To the authors' knowledge, there are no previous reports of donkeys presented with either congenital or acquired inguinal hernias.

An indirect hernia happens when a herniated bowel that has entered the inguinal canal is located within the vaginal cavity. Direct hernia exists when the abdominal bowel entering the inguinal canal is located outside the vaginal cavity. Hernia in the inguinal/scrotal region is almost entirely indirect hernias in horses. Two types of direct inguinal hernia were identified: first, a ruptured inguinal herniation in which the herniated bowel protrudes through a rent in the vaginal cavity. Second, an inguinal rupture had a herniated bowel protrudes through a rent in the peritoneum or the fascia of the abdominal musculature adjacent to the vaginal ring (Schumacher & Perkins, 2010). Indirect type of inguinal or scrotal hernias was the only one encountered in the present study.

The ileum and distal jejunum are herniated in most cases of inguinal/scrotal hernias in horses, but herniation of the large colon, omentum, or urinary bladder have also been reported in few studies

(Ivens *et al.*, 2009; Robinson & Carmalt, 2009; Cousty *et al.*, 2010). A similar finding was shown in this investigation where in all examined donkeys, the hernia sac almost always contains small intestine (ileum or distal jejunum). This is probably because the ileum and the jejunum are highly mobile and may favour inguinal or scrotal herniation (Jerbi *et al.*, 2014).

The cause of acquired inguinal or scrotal hernia is not well understood in horses. The numerous postulated causes include enlarged internal inguinal ring, any circumstances which trigger increased intra-abdominal pressure such as strenuous work, mating, abdominal trauma, and routine castration complications (Weaver, 1987; Wilderjans *et al.*, 2012). Additionally, there is a general agreement in the literature on the predisposition of draft breeds and standardbred horses. There was no history of recent breeding, trauma, or castration in any of the tested animals. All donkeys were presented in the dry season after the end of the hard work season in Egypt. Therefore we suggest that a congenitally enlarged internal inguinal ring and strenuous work may play an important role in the development of this condition in working donkeys.

Acquired inguinal/scrotal hernia is a more common finding in adult stallions (Schneider *et al.*, 1982; Spurlock & Robertson, 1988; van der Velden & Stolk, 1990), but geldings (Schneider *et al.*, 1982; van der Velden & Stolk, 1990; Bickers *et al.*, 1998) and mares (Umstead *et al.*, 1986) also can be affected less frequently. Similarly, acquired inguinal-scrotal hernia was identified in nine intact males, one gelding, and one female in this study.

The main observation in all animals was a fluctuant swelling in the inguinal or scrotal region. Differential diagnoses be-

tween the inguinal or scrotal swelling include hematocele, hydrocele, torsion of the spermatic cord, varicocele, and testicular enlargement (Schumacher & Perkins, 2010). Palpation of the scrotum and or transcutaneous scrotal ultrasonography was sufficient to confirm the diagnosis of acquired inguinal or scrotal hernia in all cases. Also, the ultrasonographic examination of the inguinal region was easily performed in standing position, without the need for any sedation or analgesia.

Inguinal or scrotal hernias are more prevalent in intact males than in geldings due to the rapid closure of the inguinal rings following castration (Schumacher & Perkins, 2010). In geldings, inguinal herniation in the majority of cases occurs immediately after the castration due to the large space created in the inguinal canal following the abrupt removal of a part of the spermatic cord that favors the herniation of abdominal viscera. Hernias that are not related to castration are extremely rare (van der Velden & Stolk, 1990). The gelding described in this study was neutered one year before herniation has taken place, so we assume that an abnormally enlarged internal inguinal ring is the underlying cause.

Every acquired inguinal hernia in horses needs immediate attention and should be treated as an emergency case due to the herniated intestine always rapidly strangulates. Several treatment options have been cited (Schneider *et al.*, 1982; Weaver, 1987; Mezerová *et al.*, 2003; Schumacher & Perkins, 2010). The reduction of the inguinal incarcerated intestine by external manual manipulation or rectal traction has been reported but is difficult and rarely successful. In our study, Primary repair of inguinal hernia was performed by surgical reduction of

hernia. Additionally, the testicle at the affected site has to be removed to make it possible to close the superficial external inguinal ring by polypropylene mesh, which is done to prevent the recurrence of the hernia. Recently, minimally invasive laparoscopic closure of the deep inguinal ring by normal ligation (Klohn & Wilson, 1996), mesh (Klohn & Wilson, 1996), or a peritoneal flap (Rossignol *et al.*, 2014) has been developed. Unfortunately, laparoscopy was not available in our study.

In conclusion, acquired inguinal herniation in donkeys is not a clinical emergency that needs prompt intervention. Ultrasonography is the method of choice for confirming the diagnosis of an inguinal hernia in donkeys. One of the main limitations of this study is the lack of laparoscopic examination to support our findings.

REFERENCES

- Bickers, R. J., R. D. Lewis, T. Hays & J. K. Noble, 1998. Acquired inguinal hernia in a gelding. *Equine practice*, **20**, 28–29.
- Coekho, C. S., Retrospective study of inguinal hernia in horses: 28 cases. In: *Proceedings of 11th Congress of the World Equine Veterinary Association*. São Paulo, p. 27.
- Cousty, M., C. Tricaud, V. Picandet & O. Geffroy, 2010. Inguinal rupture with herniation of the urinary bladder through the scrotal fascia in a Shetland pony foal. *Equine Veterinary Education*, **22**, 3–6.
- Cox, J. E., 1988. Hernias and ruptures: Words to the heat of deeds. *Equine Veterinary Journal*, **20**, 155–156.
- Huskamp B & N. Kopf, 1997. Hernia Inguinalis Incarcerata beim Pferd. *Der Praktische Tierarzt*, **78**, 217–232.
- Hutchins, D. R. & R. J. Rawlinson, 1972. Eversion as a sequel to castration of the

- horse. *Australian Veterinary Journal*, **48**, 288–291.
- Ivens, P., R. Piercy & E. Eliashar, 2009. Inguinal herniation of the large colon in a cob gelding four weeks after castration. *The Veterinary Record*, **165**, 380–381.
- Jerbi, H., A. Rejeb, S. Erdoğan & W. Pérez, 2014. Anatomical and morphometric study of gastrointestinal tract of donkey (*Equus africanus asinus*). *Journal of Morphological Sciences*, **31**, 18–22.
- Kersjes, A. W., F. Nemeth & L. J. E. Rutgers, 1985. Atlas of Large Animal Surgery Williams and Wilkins.
- Klohn, A. & D. G. Wilson, 1996. Laparoscopic repair of scrotal hernia in two foals. *Veterinary Surgery*, **25**, 414–416.
- Kovač, M., R. Aliev, T. Ippolitova & T. Zoran, 2018. Equine acquired inguinal herniation – diagnosis and treatment in 62 cases. *Veterinarski Glasnik*, **72**, 22–34.
- Mezerová, J., Z. Zert, R. Kabeš & P. Jahn, 2003. Hernia inguinalis incarcerata in horses: 43 cases. *Pferdeheilkunde*, **19**, 263–268.
- Misk, N., 1984. Ventral abdominal hernia in a donkey. *Equine practice*, **6**, 46–47.
- Moll, H. D., J. S. Juzwiak, E. M. Santschi, & D. E. Slone 1991. Small-intestinal volvulus as a complication of acquired inguinal hernia in two horses. *Journal of American Veterinary Medical Association*, **198**, 1413–1414.
- Robinson, E. & J. Carmalt, 2009. Inguinal herniation of the ascending colon in a 6-month-old standardbred colt. *Veterinary surgery*, **38**, 1012–1013.
- Rosignol, F., C. Mespoules-Rivière, A. Vitte, A. Lechartier & K. J. Boening, 2014. Standing laparoscopic inguinal hernioplasty using cyanoacrylate for preventing recurrence of acquired strangulated inguinal herniation in 10 stallions. *Veterinary Surgery*, **43**, 6–11.
- Schneider, R. K., D. W. Milne & C. W. Kohn, 1982. Acquired inguinal hernia in the horse: A review of 27 cases. *Journal of American Veterinary Medical Association*, **180**, 317–320.
- Schumacher, J. & J. Perkins, 2010. Inguinal herniation and rupture in horses. *Equine Veterinary Education*, **22**, 7–12.
- Sisson, S. & J. D. Grossman, 1953. The Anatomy of the Domestic Animals. Philadelphia, W. B. Saunders.
- Spurlock, G. H. & J. T. Robertson, 1988. Congenital inguinal hernias associated with a rent in the common vaginal tunic in five foals. *Journal of American Veterinary Medical Association*, **193**, 1087–1088.
- Umstead, J. A., B. Nyack & C. L. Padmore, 1986. Inguinal ring herniation in a female Shetland pony. *The Compendium on Continuing Education for the Practicing Veterinarian*, **8**, 164–165.
- Van der velden, M. A. & P. W. T. Stolk, 1990. Different types of inguinal herniation in two stallions and a gelding. *Veterinary Quarterly*, **12**, 46–50.
- Weaver, A. D., 1987. Acquired incarcerated inguinal hernia: A review of 13 horses. *The Canadian Veterinary Journal*, **28**, 195–199.
- Wilderjans, H., M. Meulyzer & O. Simon, 2012. Standing laparoscopic peritoneal flap hernioplasty technique for preventing recurrence of acquired strangulating inguinal herniation in stallions. *Veterinary Surgery*, **41**, 292–299.

Paper received 05.10.2020; accepted for publication 06.11.2020

Correspondence:

Mohamed A. Marzok
Department of Veterinary Surgery,
Anesthesiology and Radiology,
Faculty of Veterinary Medicine,
Kafrelshiekh University, 33516, Egypt
tel.: +966 56513302;
e-mail: marzok2000@hotmail.com