

Short communication

HISTOLOGICAL EVIDENCE OF A RESPIRATORY SYNCYTIAL VIRUS INFECTION IN PNEUMONIC LUNGS OF SHEEP IN AL-QASSIM AREA, KINGDOM OF SAUDI ARABIA

A. A. AL-SADRANI & E. B. ABDELSALAM

Department of Veterinary Medicine, College of Agriculture and Veterinary Medicine, Qassim University, Burraydah; Kingdom of Saudi Arabia

Summary

Al-Sadrani, A. A. & E. B. Abdelsalam, 2010. Histological evidence of a respiratory syncytial virus infection in pneumonic lungs of sheep in Al-Quasim area, Kingdom of Saudi Arabia. *Bulg. J. Vet. Med.*, 13, No 3, 186–189.

Histological alterations indicative of a respiratory syncytial virus (RSV) infection were detected in the lung tissue of *Mannheimia haemolytica*-infected sheep in Al-Qassim Province, Kingdom of Saudi Arabia. Affected lungs showed prominent inflammatory alterations dominated by acute capillary congestion and extensive loss of airspaces due to massive cellular infiltration into the pulmonary alveoli. A number of multinucleated syncytial giant cells of variable size and shape were randomly scattered on the lung parenchyma. In addition, acute necrotizing bronchiolitis was also observed with some proliferative alterations and presence of intracytoplasmic inclusion bodies in the bronchiolar epithelium. The histological evidence of a RSV infection in the lung tissue of *Mannheimia haemolytica*-infected sheep described in the present report emphasizes the role of the virus in the pathogenesis of bacterial pneumonias in sheep.

Key words: lung, pneumonia, respiratory syncytial virus, Saudi Arabia

Respiratory syncytial virus (RSV) is an RNA virus classified as a pneumovirus within the Paramyxoviridae family (McIntosh & Chanock, 1990). The name of the virus was related to its characteristic cytopathic effect in forming syncytial giant cells in the lung tissue of infected animals. The human strain of respiratory syncytial virus (HRSV) is a major cause of lower respiratory tract infections in infants and young children producing severe pneumonia and bronchiolitis (Tripp, 2004; Leung *et al.*, 2005). Bovine and ovine forms of

the virus were also recognized as important respiratory pathogens and have been isolated from cattle and sheep with various types of upper and lower respiratory tract infections ranging from rhinitis, tracheitis, bronchitis, bronchiolitis and mild bronchopneumonia (Trigo *et al.*, 1984; Evermann *et al.*, 1985; Kovarcik, 1999; Valarcher & Taylor, 2007; Bell, 2008). However, primary invasions with RSV were frequently complicated by serious secondary bacterial infections resulting in fatal or more severe bronchopneu-

monia (Babiuk *et al.*, 1988; Larsen, 2000; Mohamed & Abdelsalam, 2008). Although RSV infection is of worldwide prevalence all over the continents, no reports are currently available on its existence in farm animals in the Kingdom of Saudi Arabia or other states in the Gulf region. The present communication, hence, provides an initial histological evidence of the occurrence of RSV in pneumonic lungs of a local breed of sheep with acute respiratory disease.

Six female Nagdi sheep of an average age of nine months were submitted for routine necropsy at the Veterinary Teaching Hospital, Qassim University. The attached clinical history indicated a sudden occurrence of an acute respiratory disease of a febrile nature in a sheep flock of 150 animals kept in an open range pasture in a nearby location. More than 25% of the total sheep population were affected, particularly relatively young animals (6 to 9 months of age). Twelve animals have already been found dead in pasture while the rest of the sheep responded positively to extensive treatment with antibiotic (Terramycin/LA; injectable oxytetracycline solution; Pfizer). Only the above-mentioned six sheep were brought to the University Veterinary Teaching Hospital for treatment. However, they were in a very critical condition and died on arrival.

Detailed post mortem examination was performed on the dead animals with a special emphasis on the respiratory system. Representative samples of affected lung tissues were immediately fixed in 10% buffered formalin solution for histopathological processing and staining with haematoxylin and eosin (H&E) by the paraffin wax method described by Bancroft & Gamble (2002). Bacteriological swabs from pneumonic lungs and tracheal effusions were initially cultured in blood

agar and Mac Conkey agar plates. They were then subcultured in brain-heart infusion agar. Isolates of purified colonies were identified by standard methods (Barrow & Feltham, 1993). Further identification was also obtained by the Vitek 2 automated identification system (Vitek Bio-Mérieux Inc., Durham, North Carolina).

The necropsy findings of four animals were dominated by acute bronchopneumonia with cranioventral involvement of the apical lobes together with sizable portions of the intermediate lobes of both lungs. The affected parts were dark red in colour, firm in consistency and partially covered with fibrinous strands. The cut surface was also firm and dark red in colour. Appreciable amount of frothy fluid was oozing from the trachea and bronchi. The lungs of the other two animals were remarkably congested and oedematous with scattered foci of pneumonic consolidations on the cardiac and anterior parts of the diaphragmatic lobe.

The histopathological examination of affected lungs revealed acute inflammatory reaction with prominent vascular alterations manifested by severe capillary congestion, thrombosis and scattered haemorrhages in the lung parenchyma and subpleural spaces. These changes were accompanied by massive diffuse infiltration of neutrophils, lymphocytes and macrophages into the pulmonary alveoli resulting in extensive loss of air spaces. In addition, a number of multinucleated syncytial giant cells were randomly scattered on the lung parenchyma (Fig. 1). These were variable in size, almost round or irregular in shape and contained several nuclei. Inflammatory changes were also present in the vicinity of bronchi and bronchioles which showed variable degrees of necrotic and cellular degenerations and desquamation of the bronchial epithelium. Many of

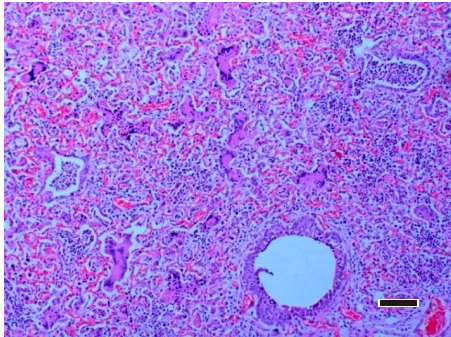


Fig. 1. Infected lung of sheep showing acute bronchiolitis and loss of airspaces. Note the presence of multinucleated syncytial cells. H & E; bar = 200 μ m.

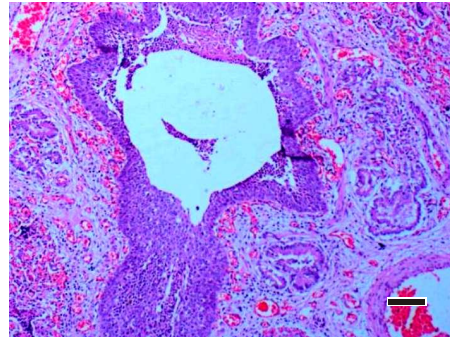


Fig. 2. Hyperplasia of the bronchiolar epithelium. H & E; bar = 100 μ m.

the affected bronchioles were partially obliterated with cellular debris consisting of neutrophils, macrophages and desquamated epithelium.

Prominent hyperplasia of the bronchial and bronchiolar epithelium, particularly in the least affected areas was also observed (Fig. 2). Eosinophilic intracytoplasmic inclusion bodies were also detected in the bronchiolar epithelium. They were spherical or oval in shape, purple in colour and surrounded by an empty halo (Fig. 3).

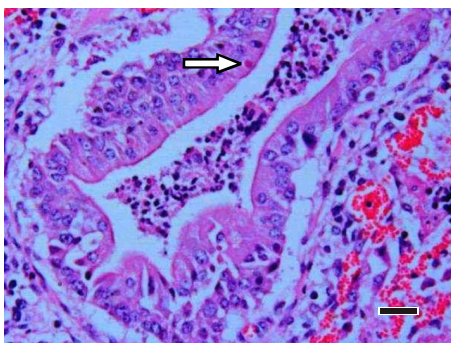


Fig. 3. An intracytoplasmic inclusion body (arrow) in the bronchiolar epithelium. H & E, bar = 20 μ m.

The histopathological alterations of

the pneumonic sheep lungs in the present communication were similar to those previously reported for RSV infected sheep and cattle (Kimman *et al.*, 1989; Bryson, 1993; Ellis *et al.*, 1996; Larsen *et al.*, 2001; Valarcher & Taylor, 2007). However, the results from bacteriological isolations and identification indicated the presence of *Mannheimia haemolytica* in all bacteriological swabs obtained from the infected lungs. The present findings therefore provided a strong evidence of a concurrent or a previous exposure of sheep to some kind of a respiratory syncytial virus complicated by *Mannheimia haemolytica* infection. The alleged virus is probably of an ovine origin due to the fact that cattle populations are totally absent and not usually raised in this area. The histological evidence of the presence RSV in the lung tissue of *Mannheimia haemolytica*-infected sheep supports the role of the virus in the pathogenesis of bacterial pneumonias in sheep.

REFERENCES

- Babiuk, L. A., M. J. Lawman & H. B. Ohmann, 1988. Viral-bacterial synergistic in-

- teraction in respiratory disease. *Advances in Virus Research*, **35**, 219–249.
- Bancroft, J. D. & M. Gamble, 2002. Theory and Practice of Histological Technique, 5th edn. Churchill Livingstone.
- Barrow, G. I. & R. K. A. Feltham, 1993. Cowan and Steel's Manual for Identification of Medical Bacteria, 3rd edn, Cambridge University Press, pp. 50–150.
- Bryson, D. E., 1993. Necropsy findings associated with BRSV pneumonia. *Veterinary Medicine*, **88**, 874–899.
- Bell, S. 2008. Respiratory disease in sheep. 1. Differential diagnosis and epidemiology. *In Practice*, **30**, 200–207.
- Ellis, J. A., H. Philibert, K. Weast, E. Clark, K. Martin & D. Haines, 1996. Fatal pneumonia in adult dairy cattle associated with active infection with bovine respiratory syncytial virus. *Canadian Veterinary Journal*, **37**, 103–105.
- Evermann, J. F., H. D. Liggitt, S. M. Parish, A. C. S. Ward & B. R. Leamaster, 1985. Properties of a respiratory syncytial virus isolated from a sheep with rhinitis. *American Journal of Veterinary Research*, **46**, 947–951.
- Kimman, T. G., P. J. Straver & G. M. Zimmer, 1989. Pathogenesis of bovine respiratory syncytial virus infection. Morphologic and serologic findings. *American Journal of Veterinary Research*, **50**, 684–693.
- Kovarcik, K., 1999. Isolation of bovine respiratory syncytial virus during an outbreak of acute respiratory disease in calves. *Veterinary Medicine*, **44**, 121–127.
- Larsen, L. E., 2000. Bovine respiratory syncytial virus (BRSV): A review. *Acta Veterinaria Scandinavica*, **41**, 1–21.
- Larsen, L. E., C. Tegmetmeier & E. Pedersen, 2001. Bovine respiratory syncytial virus pneumonia in beef cattle despite vaccination. *Acta Veterinaria Scandinavica*, **42**, 113–121.
- Leung, A. K. C., J. D. Kellner & H. Dele Davies, 2005. Respiratory syncytial virus bronchiolitis. *Journal of the National Medical Association*, **97**, 1708–1713.
- McIntosh, K. & R. M. Chanock, 1990. Respiratory syncytial virus. In: *Virology*, 2nd edn, eds Fields, B. M. & D. M. Knipe, Raven Press, New York, N.Y., pp. 1045–1072.
- Mohamed, R. A. & E. B. Abdelsalam, 2008. A review on pneumonic pasteurellosis (respiratory mannheimiosis) with emphasis on pathogenesis, virulent mechanisms and predisposing factors. *Bulgarian Journal of Veterinary Medicine*, **11**, 139–160.
- Trigo, F. J., R. G. Breeze, J. F. Evermann & A. M. Gallina, 1984. Pathogenesis of experimental bovine respiratory syncytial virus infection in sheep. *American Journal of Veterinary Research*, **45**, 1663–1670.
- Tripp, R. A., 2004. Pathogenesis of respiratory syncytial virus infection. *Viral Immunology*, **17**, 165–181.
- Valarcher, J-F. & G. Taylor, 2007. Bovine respiratory syncytial virus infection. *Veterinary Research*, **38**, 153–180.

Paper received 28.04.2010; accepted for publication 05.07.2010

Correspondence:

Prof. Dr. E. B. Abdelsalam,
Department of Veterinary Medicine,
College of Agriculture and
Veterinary Medicine,
Qassim University,
P. O. Box 6622,
Burraydah 51452, Kingdom of Saudi Arabia
E-mail: mahibil@hotmail.com